

## CGDENT AND GC AWARD FOR FOUNDATION TRAINEES ENTRY GUIDANCE 2024/25

The CGDent and GC Award for Foundation Trainees is open to **Dentists** and **Dental Therapists** who qualified in 2024 in the UK or Ireland or are undertaking Dental Foundation Training or Dental Vocational Training in 2024/25. This is your opportunity to gain professional recognition for your clinical skills, and the high standard of care you have provided to your patient.

To enter, you must submit a suitable case that you are about to start treating. You will find details on case criteria further in the guidance.

### KEY DATES

	Initial entries close	Friday 14 February 2025
	Final cases submitted by	Friday 11 April 2025
	Winners announced by	May 2025
	Winners' trip to Belgium	9 – 12 July 2025
	Composite layering course	10 & 11 July 2025

### HOW TO ENTER

1. Identify an appropriate case to enter the competition
2. Complete our online entry form, including pre-op photos to ensure case eligibility
3. Carry out restorative treatment
4. Submit your case

1. The first step is to identify a case amongst your patients that you would like to enter in the competition (see the **Case Eligibility Criteria**). Ensure you gain your patient's consent as well as consent from your Educational Supervisor or NHS Trust/University, before you enter the competition. You will also need your patient's

consent to **publish** their pre-op and post-op photos (mouth only) in professional publications only, in case you are a winner.

2. Ready to enter? First create a free account on the College website or sign in to an existing account. Please **check your junk box** if you do not receive a confirmation email.



Create a free online account here: [cgdent.uk/register](https://cgdent.uk/register)  
Or sign in here: [cgdent.uk/login](https://cgdent.uk/login)

Complete our online entry form and attach **up to seven** pre-op photos of the case you plan to treat.

**IMPORTANT** For your case to be accepted into the competition, your photographs **MUST:**

- Be taken on a camera with the **correct date and time** settings.
- Be high-resolution Jpg files, **max 3MB** each.
- Correctly depict the four clinical views as specified below:
  - A. Face on retracted view.
  - B. Left lateral retracted view.
  - C. Right lateral retracted view.
  - D. Occlusal view of the arch being treated.

We appreciate that if your case is a **trauma case**, taking all these photos may not be a priority – one view of the teeth involved with and without a retractor and an occlusal view and radiograph just showing the affected tooth or teeth will suffice.

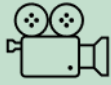In addition, to support your case, you *may* also include any of the following but they are not essential:

- E. Views A, B, C *without* retractors.
- F. Smile view.
- G. Full face view.

Photos that do not adhere to these criteria will not be accepted into the competition. **Click here to see examples of photos that are not acceptable.**

Check the **Presenting your Final Case** section for final case requirements to ensure

you have all the pre-op photos you will need.



**IMPORTANT: WATCH THIS VIDEO for tips on taking effective clinical photographs**



**Complete the online entry form here: [cgdent.uk/cgdent-gc-award](https://cgdent.uk/cgdent-gc-award)**

We will check the eligibility of your case and let you know if your case is valid to enter the competition.

If, after your initial entry, you find a case you would prefer to enter, you may contact us **before the initial entry deadline** with new pre-op photographs and we will confirm if the case is eligible. Please email us in the first instance at [contact@cgdent.uk](mailto:contact@cgdent.uk)



**The award closes for initial entries at 23:59 on Friday 14 February 2025.**

**You may not change your case after this date, without exception.**

We are accepting a maximum number of 200 entries and once that cap has been reached, the competition will close to initial entries. However, entrants will still be able to change their case until Friday 14 February 2025.

3. Carry out your treatment on your patient.
4. Once completed, submit your case by the final entry date. Your case should be submitted as a PDF and include:
  - A. An outline of the patient's expectations regarding their appearance as well as any other issues raised by the patient.
  - B. Short summary of the proposed treatment plan.
  - C. Reflection.
  - D. Pre-op and post-op photographs and radiographs if appropriate.

You will find more details about compiling your final case below in the **Presenting Your Final Case** section, including an example of a final case and a guidance video.



Submit your final case PDF here: [cgdent.uk/cgdent-and-gc-award](https://cgdent.uk/cgdent-and-gc-award)



You may submit your case as soon as you have completed it, but the final case submission deadline is 23:59 on Friday 11 April 2025.

**Without exception, we will not accept individual requests for a deadline extension.**

## CASE ELIGIBILITY CRITERIA

Your case treatment must involve more than one tooth and include the use of composite to restore teeth, in addition to other restorative techniques.

A single tooth would be acceptable if it involves the treatment of a badly discoloured tooth or trauma. The overall treatment may include a single veneer or crown or an adhesive bridge but only as part of the full restorative treatment with composite. Aesthetics posterior to the first premolar teeth can be included if part of the treatment plan, but these restorations will not be included in the judging process.

The following treatments are eligible for entry:

- Treatment for caries.
- Treatment for trauma.
- Treatment for tooth wear.
- Aesthetic bonding which could include whitening and/or minor orthodontic tooth movement. Orthodontics could have been started by a predecessor and completed by you, but you would need to carry out the restorative phase of treatment. Your pre-op photo should show the first day you take over the patient's treatment.

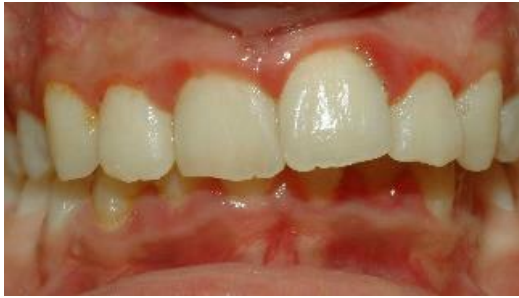

**PERIO TIP: in all cases, it is important to treat periodontal issues alongside the restorative treatment. Judges will deduct marks for cases where there has not been a significant improvement in periodontal issues.**

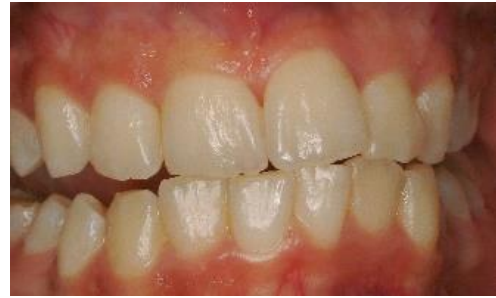## Example periodontal cases

These photographs demonstrate the level of improvement we expect to see in cases which include periodontal issues.

**Pre-op photograph**



**Post-op photograph**



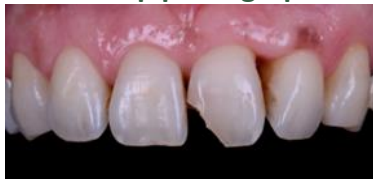### Example restorative cases

These photographs are just a few examples of the types of case you could submit. Further examples are provided at the end of this document.

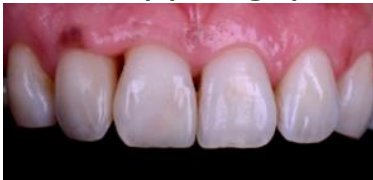#### **CASE A**

Restoration of a fractured tooth and replacement filling

**Pre-op photograph**



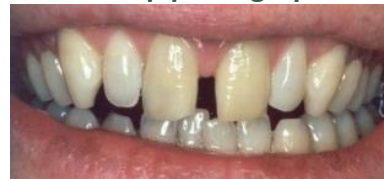**Post-op photograph**



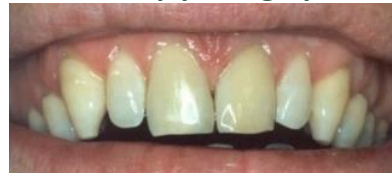#### **CASE B**

Aesthetic composite space closure

**Pre-op photograph**



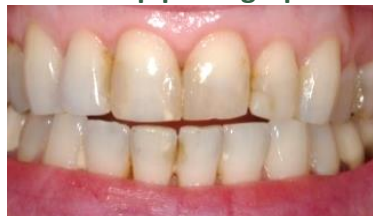**Post-op photograph**



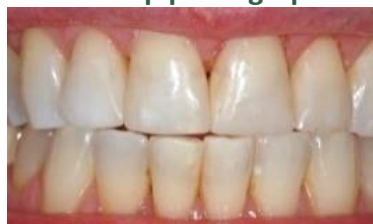#### **CASE C**

Replacement of old unsightly composites

**Pre-op photograph**



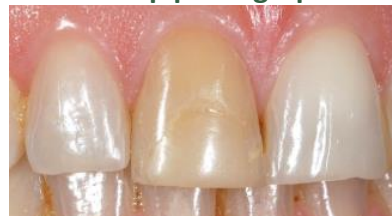**Post-op photograph**



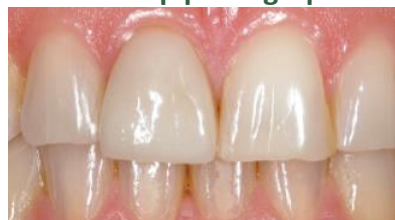#### **CASE D**

Internal whitening and composite veneer

**Pre-op photograph**



**Post-op photograph**





More cases are shown at the end of this document and you can see the previous winning cases here: [cgdent.uk/cgdent-gc-award-winners](https://cgdent.uk/cgdent-gc-award-winners)

## PRESENTING YOUR FINAL CASE

Your final case should consist of case photographs that illustrate the treatment you carried out, supported by a short written clinical record. You should include pre-op and post-op photographs and you may include interim photographs if you think these are relevant to your case.



**TIP:** judges will predominantly assess your case on the strength of your **photographs** and **reflection**, looking at your clinical dentistry skills, how your treatment has benefited your patient and what you have learnt from carrying out the case.

Save your case as a PDF, with your full name in the file name, and submit it to us on the CGDent website.



Submit your final case PDF here: [cgdent.uk/cgdent-and-gc-award](https://cgdent.uk/cgdent-and-gc-award)

Here is an outline of the sections you should include, indicating the word limits allocated. **We have also created an example of a final case for you to follow and a video that includes formatting tips (see below).**

### CLINICAL RECORD

(Up to 600 words in total)

#### To include:

- **Presentation on initial visit:** initial complaint/history of clinical presentation
- **Relevant medical, dental, social history:** only include this if clinically relevant, otherwise N/A
- **Brief record of initial clinical presentation:** extra oral and intra oral – radiograph(s) only if clinically necessary
- **Brief description of initial treatment plan,** including an outline of any relevant treatment discussions with your patient
- **Pre-op photographs:**

- A. Face on retracted view.
- B. Left lateral retracted view.
- C. Right lateral retracted view.
- D. Occlusal view of the arch being treated.

Optional photo views to include *only* if they support your case:

- E. Views A, B, C *without* retractors.
  - F. Smile view.
  - G. Full face view.
  - H. Pre-op dated radiographs, only if clinically necessary.
- **Interim photographs and radiographs**, include if relevant to the final outcome.

## RECORD OF TREATMENT SEQUENCE

A written treatment record is **not needed in most cases** and should only be included for more complex cases (up to 250 words)

- **Post-op photographs**
  - The same format as pre-op photographs listed above
  - Include post-op radiographs, only if clinically necessary
- **Pre-op and post-op photographs positioned next to each other for comparison**



**POST-OP PHOTOS TIP:** as well as taking post-op photos immediately after treatment, we recommend that you also photograph your case **ONE WEEK** after treatment, to allow the teeth to rehydrate and look their best.

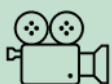## REFLECTION

(up to 250 words)

Include learnt experiences, problems you encountered and how you addressed them, what you have learnt and how you would have treated the case differently. If your patient refused the treatment you recommended, tell us about it here and how you adapted the treatment to suit the patient's requirements or financial restrictions. Or if it all went smoothly, just say so.

## FINAL CASE SUBMISSION EXAMPLE AND GUIDANCE VIDEO

Here is an example of a final case for you to follow. It is important that you watch our guidance video for tips on how to format your case.



**IMPORTANT: WATCH THIS VIDEO for final case formatting tips**

**CGDent and GC Award for Foundation Trainees**

**DR FRED BLOGGS - CASE PRESENTATION EXAMPLE**

**CLINICAL RECORD ON PRESENTATION**

- Pt presented – no pain
- Concerned with her gappy appearance
- Dislikes her midline gap - would like it closed
- Knows she was born without her two lateral incisors and would like those to look less pointy and more like normal front teeth
- Was unaware that her teeth may look larger than they are already if the spaces are closed
- Was not prepared to pay for a diagnostic wax up – but happy to proceed as she understands the procedure is additive and so the additions can be removed or modified if she does not like them

**Discussed**

- The choice of doing nothing – not acceptable to the patient
- Orthodontics – does not want to wear braces long term – she was told that it would involve moving canines which would be a slow prolonged treatment option – over a year
- Did not appreciate the tooth sized space left following orthodontics would require either a denture or an adhesive bridge – pt too young for implants as bone growth continues until around the age of 23 or so – implants submerging is a possibility
- Pt does not want a denture – has a friend who had an adhesive bridge that keeps coming off and does not one of these either

**Further discussion** – pt decided she would prefer composite space closure – does not want her teeth cut, so will not accept veneers. Appreciates composite could chip or discolour but is prepared to take that risk.

**Discussed whitening** –

- pt informed that if whitening is a possible choice at some point in the future, the composite will not change colour and so there would be a cost to re-veneer the space closures provided
- pt did not appreciate that composite cannot be whitened and would like to proceed with that first

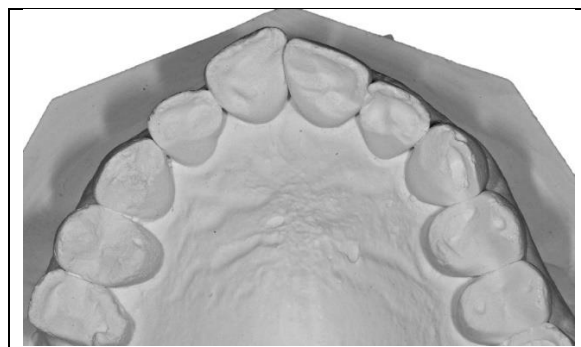
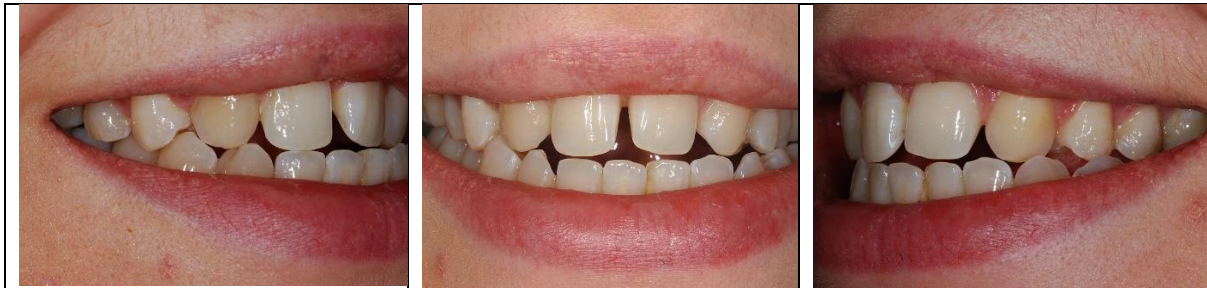**Clinical observations** – the patient has a mild anterior open bite so the prognosis of longevity is very good and chances of chipping very low – pt informed that eg opening packaging could cause debonding and replacement would be at the patient expense



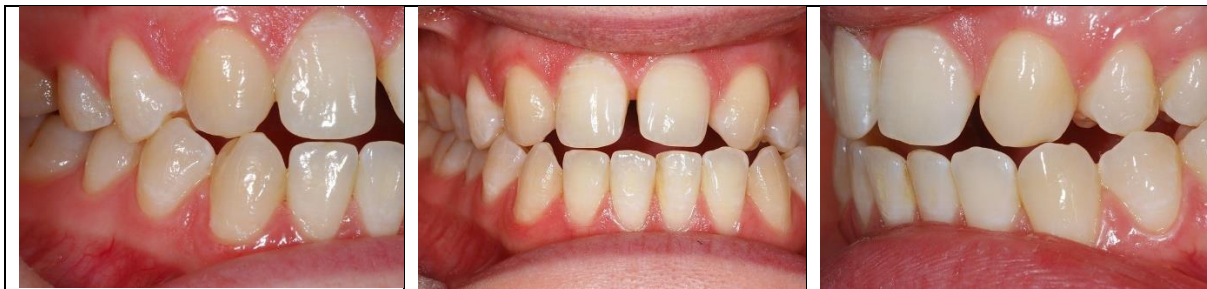**Only other points you may feel are really pertinent to the case should be briefly included:**

There were two possible treatment options to provide the same outcome for this case – freehand or diagnostic wax up and then using a putty stent. I chose to do this case freehand.

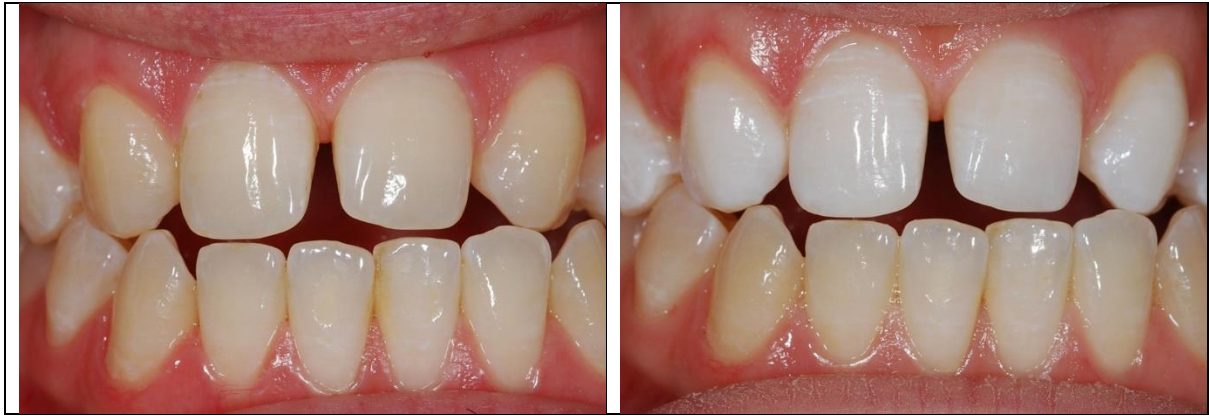**Medical History, periodontal chartings etc are not required unless there are specific issues which you had to take into consideration as part of the treatment plan.**



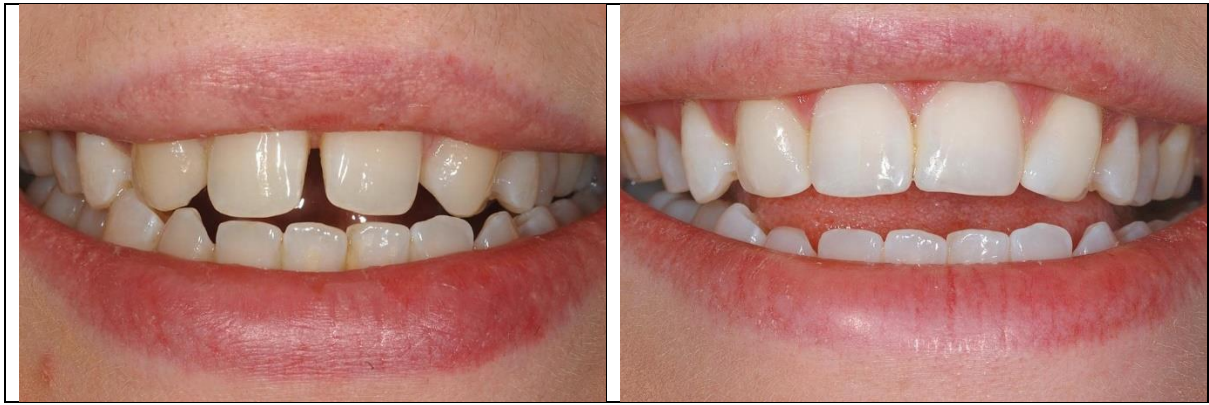Occlusal view of the arch being treated



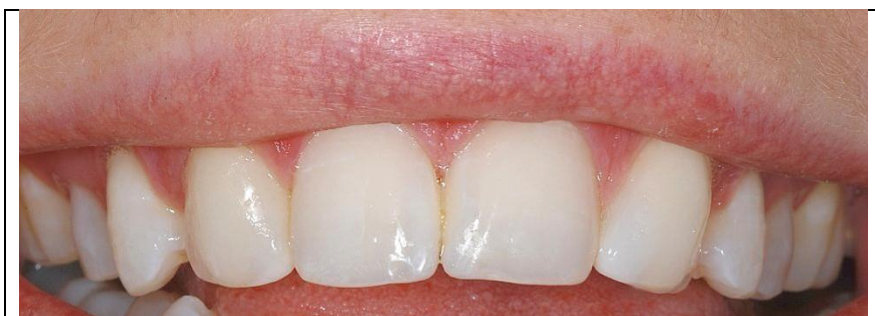Retracted view prior to treatment



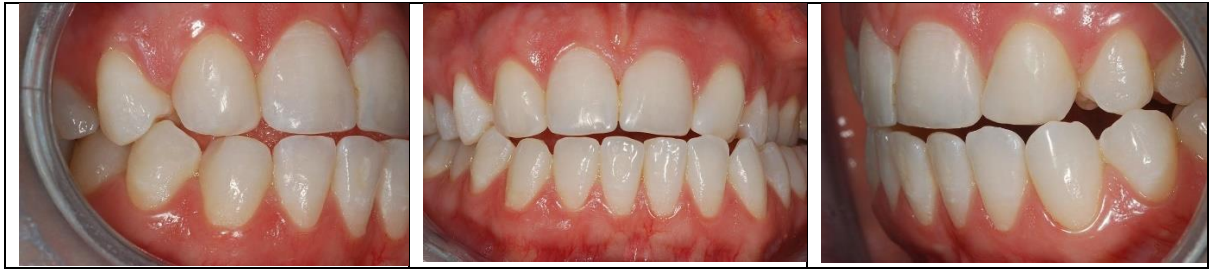Pre and post whitening



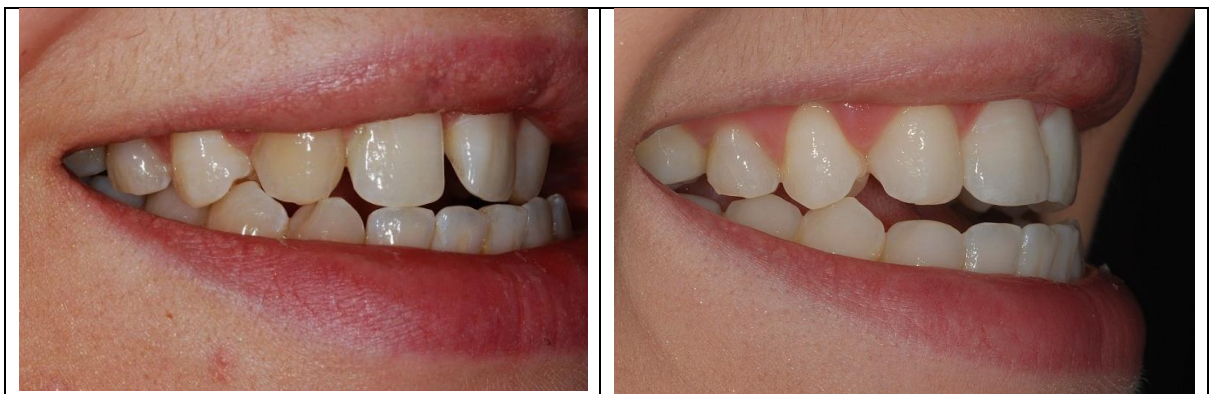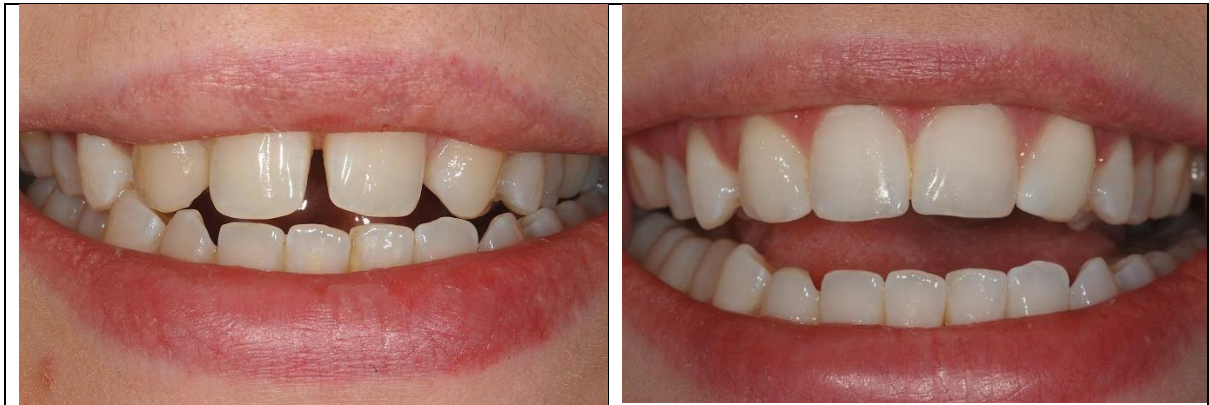Pre and post space closure



Close up view



Post op retracted view



Pre and post op views

**REFLECTION**

**The Reflection is a key part of the case.** In this section, you can write about what you have learnt by treating this case. Did you encounter any problems? How did you address them? How would you treat the case differently if you could do it again? If your patient refused the treatment you recommended, tell us about it here and how you adapted the treatment to suit the patient's requirements or financial restrictions. Or did it just go smoothly, in which case just say so.

## SELECTING THE WINNERS

A maximum of 18 winners will be selected for the 2024/25 CGDent and GC Award for Foundation Trainees.



**The winners will be announced in May 2025.**

The Judging panel comprises the Trustees of The Tom Bereznicki Charitable Educational Foundation and suitably qualified members of the College, and their decision is final. The Trustees of The Tom Bereznicki Charitable Educational Foundation represent the College of General Dentistry and GC UK.

Winners will be invited to attend the CGDent Fellows' Summer Reception, held in London in June 2025, in recognition of their achievement (date to be confirmed).

Each winner will receive a fully funded place on a two-day composite layering course at GC's Education Campus in Leuven, Belgium. The prize includes travel costs to and from Belgium, hotel accommodation and meals.

Winners based more than 30 miles from London can reclaim their return travel costs to London on public transport. Winners based within 30 miles of London will be expected to travel to and from London St Pancras Station at their own expense.



**BEFORE ENTERING THE AWARD, ENSURE YOU ARE FREE TO ATTEND THE TRIP ON 9-12 JULY 2025.**

- **Wed 9 July:** travel from London to Belgium
- **Thurs 10 July & Fri 11 July:** composite layering course
- **Sat 12 July:** travel from Belgium to London

The course dates are non-transferable. You must ensure you are able to travel on the dates provided before you enter the competition. If you are chosen as one of the winners and are not able to attend the course on these dates, your place may be given to another entrant.

When the course has been completed, winners will also receive a CPD certificate.

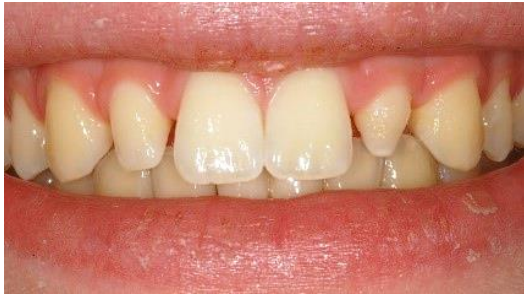**Scroll down to the next page to see further examples of eligible cases.**

## ADDITIONAL EXAMPLE CASES

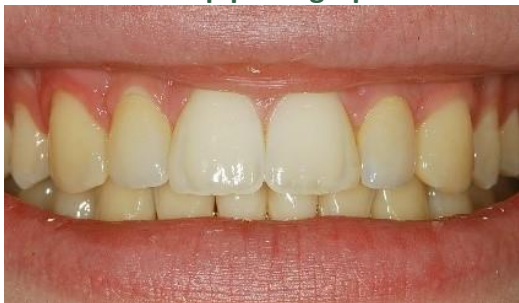### CASE E

Composite build up peg laterals and spacing

**Pre-op photograph**



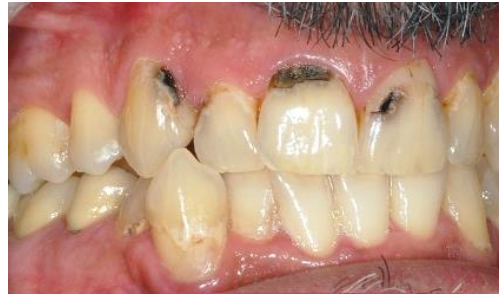**Post-op photograph**



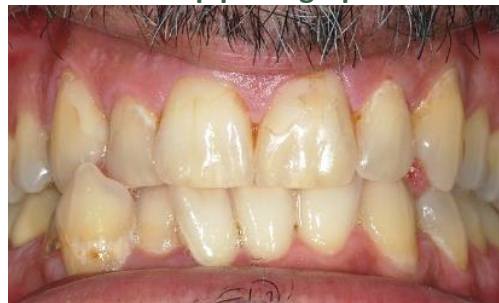### CASE F

Restoration of carious teeth

**Pre-op photograph**



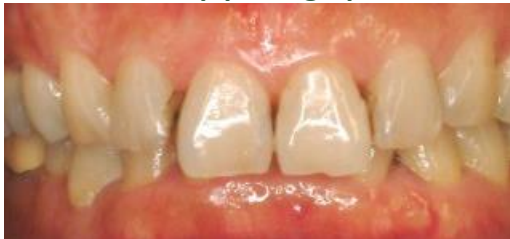**Post-op photograph**



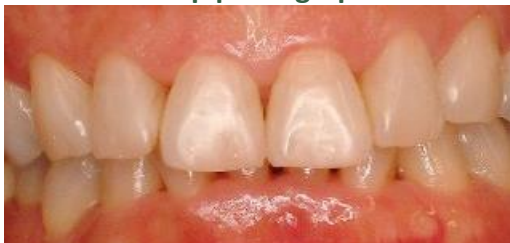### CASE G

Aesthetic improvements with composite

**Pre-op photograph**



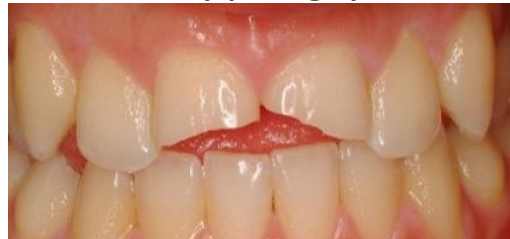**Post-op photograph**



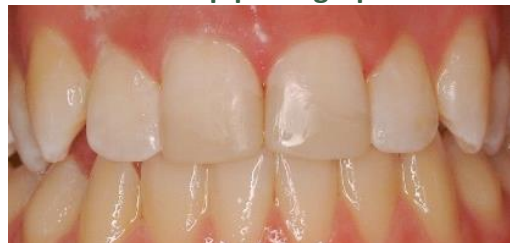### CASE H

Emergency restoration of fractured teeth

**Pre-op photograph**

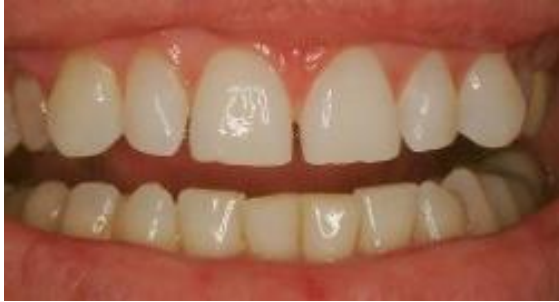

**Post-op photograph**

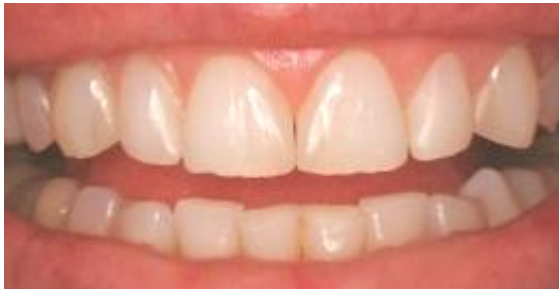

**CASE I**

Cosmetic space closure with composite  
**Pre-op photograph**

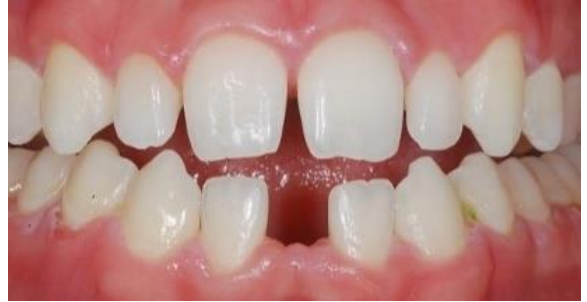

**Post-op photograph**

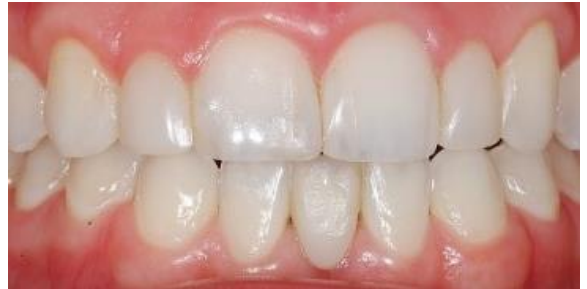

**CASE J**

Adhesive bridge and cosmetic composite bonding  
**Pre-op photograph**

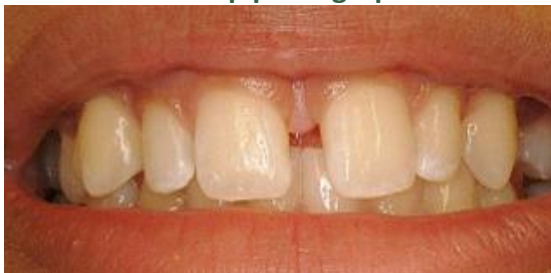

**Post-op photograph**

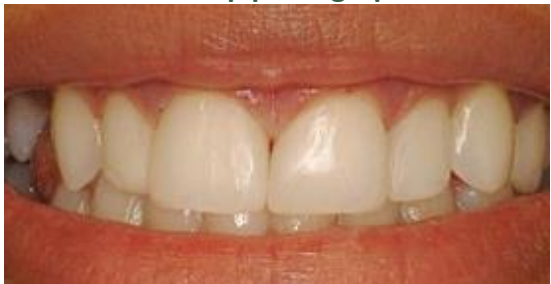

**CASE K**

Cosmetic composite space closure  
**Pre-op photograph**

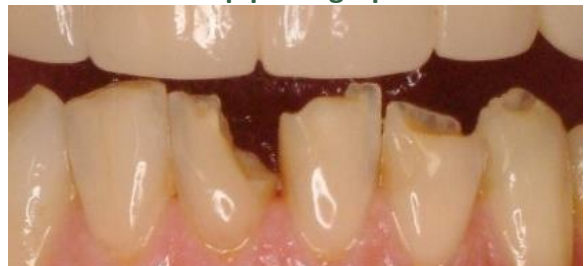

**Post-op photograph**

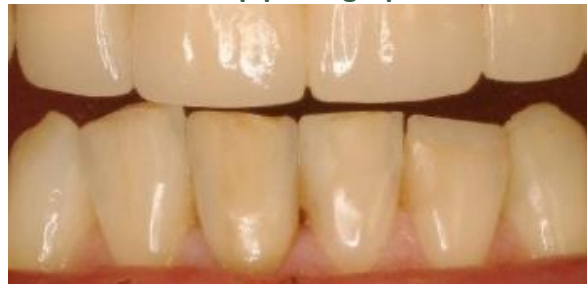

**CASE L**

Post trauma cosmetic composite repair  
**Pre-op photograph**



**Post-op photograph**



**Photo credits: Case A courtesy of GC – all other clinical cases courtesy of Dr Tom Bereznicki**