

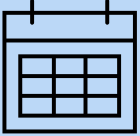
TOM BEREZNICKI AWARD FOR ADVANCED AESTHETIC DENTISTRY, developed in conjunction with CGDent and Dentsply Sirona

ENTRY GUIDANCE 2024/25

The Tom Bereznicki Award for Advanced Aesthetic Dentistry is open to Dentists who qualified in the UK or Ireland between **2019 to 2023**, or who qualified overseas between 2019 to 2023 and have been practising in the UK for at least the past two years. This is your opportunity to showcase your aesthetic dentistry skills, and the high standard of care you provide to your patients.

To enter, you must submit a suitable case that you are **about to start treating**. You will find details on case criteria further in the guidance.

KEY DATES

| | | |
|---|--------------------------|---|
|  | Initial entries close | Friday 2 May 2025 |
| | Final cases submitted by | Friday 5 September 2025 |
| | Winners announced by | October 2025 |
| | Digital Dentistry course | 14-15 November 2025 OR 28-29 November 2025 OR January 2026 (date tbc) |

HOW TO ENTER

1. Identify an appropriate case to enter the competition
 2. Complete our online entry form, including pre-op photos to ensure case eligibility
 3. Carry out aesthetic treatment
 4. Submit your case
-
1. The first step is to identify a case that you would like to enter in the competition (see the **Case Eligibility Criteria**). Ensure you gain your patient's consent before you enter the competition. You will also need your patient's consent to **publish** their pre-op

and post-op photos (mouth only) in professional publications including online, in the event that you are successful in the competition.

2. Ready to enter? First create a free subscriber account on the College website or sign in to an existing account. Please **check your junk box** if you do not receive a confirmation email.



Create a free online account here: cgdent.uk/register-new
Or sign in here: cgdent.uk/login

Complete our online entry form and attach up to **nine** pre-op photos of the case you plan to treat.

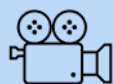IMPORTANT For your case to be accepted into the competition, your photographs **MUST:**

- Be taken on a camera with the **correct date and time** settings.
- Be high-resolution Jpg files, **max 3MB** each.
- Correctly depict the clinical views as specified below:
 - A. Face on retracted AND non-retracted views.
 - B. Left lateral retracted AND non-retracted views.
 - C. Right lateral retracted AND non-retracted views.
 - D. Occlusal view of the arch(es) being treated.
 - E. Smile view.
 - F. Full face view (optional).

We appreciate that if your case is a **trauma case**, taking all these photos may not be a priority – one view of the teeth involved with and without a retractor and an occlusal view and radiograph just showing the affected tooth or teeth will suffice.

Photos that do not adhere to these criteria will not be accepted into the competition. **Click here to see examples of photos that are NOT acceptable.**

Check the **Presenting your Final Case** section for final case requirements to ensure you have all the pre-op photos you will need.



IMPORTANT: WATCH THIS VIDEO for tips on taking effective clinical photographs



Complete the online entry form here: <https://cgdent.uk/tom-bereznicki-award-for-advanced-aesthetic-dentistry/>

We will check the eligibility of your case and let you know if your case is valid to enter the competition.

We are accepting a maximum number of 150 entries and once that cap has been reached, the competition will close to initial entries.

If, after your initial entry, you find a case you would prefer to enter, you may contact us before the initial entry deadline of **Friday 2 May 2025** with new pre-op photographs and we will confirm if the case is eligible. Please email us in the first instance at contact@cgdent.uk

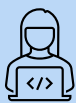

The award closes for initial entries at 23:59 Friday 2 May 2025.

You may not change your case after this date, without exception.

3. Carry out your treatment on your patient.
4. Once completed, submit your case by the final entry date. Your case should be submitted as a PDF and include:
 - A. An outline of the patient's expectations regarding their appearance as well as any other issues raised by the patient.
 - B. Short summary of the proposed treatment plan.
 - C. Reflection.
 - D. Pre-op and post-op photographs, and radiographs only if appropriate.

You will find more details about compiling your final case below in the **Presenting Your Final Case** section, including an example of a final case and a guidance video.



Submit your final case PDF here: cgdent.uk/tom-bereznicki-award-for-advanced-aesthetic-dentistry



You may submit your case as soon as you have completed it, but the final case submission deadline is 23:59 on Friday 5 September 2025.

Without exception, we will not accept individual requests for a deadline extension.

CASE ELIGIBILITY CRITERIA

As the prize for this Award is a two-day, hands-on digital dentistry course, the competition is aimed at dentists who have very limited experience with a digital workflow. If you are already fully conversant with digital dentistry, the course might not be suitable for you so there may be little merit in entering the award.

Your case:

- must be **predominantly analogue** with the exception of clear aligner orthodontics or one digital unit such as a digital crown.
- must involve **more than one tooth**, including **at least one anterior tooth**, with the exception of a trauma case or a badly discoloured tooth.
- must **include composite** to restore some of the teeth.
- may include up to two analogue crowns or an adhesive bridge alongside normal restorative procedures.
- may include aesthetics posterior to the first premolar teeth but these restorations will not be included in the judging process.
- may include **periodontal procedures** such as crown lengthening.
- may include specific elements that have been undertaken by a specialist – specify the details in the final case presentation.

The following treatments are eligible for entry. **For a fuller range see the example case photos further in this document.**

- Treatment of caries.
- Treatment of trauma.
- Treatment of tooth wear.
- Aesthetic bonding which could include whitening and/or minor orthodontic tooth movement. Orthodontics could have been started by a predecessor and completed by you, but you would need to carry out the restorative phase of treatment. Your pre-op photo should show the first day you take over the patient's treatment.

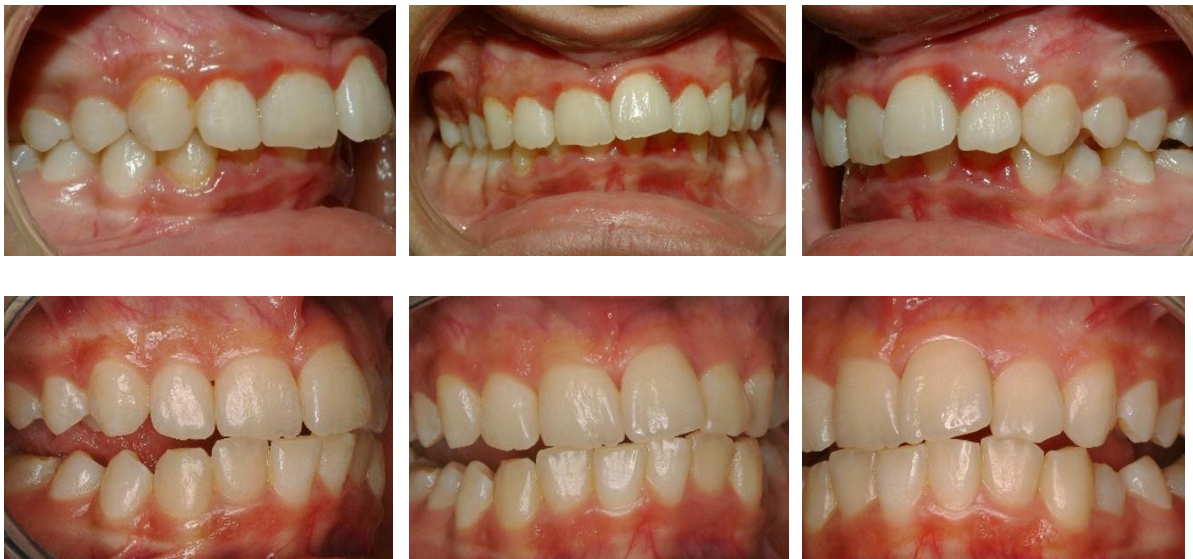Entrants will have at least four months to complete the treatment.



PERIO TIP: in all cases, it is important to treat periodontal issues alongside the aesthetic treatment. Judges will deduct marks for cases where there has not been a significant improvement in periodontal issues with the exception of trauma cases.

Example periodontal case

These photographs demonstrate the level of improvement we expect to see in cases which include periodontal issues. Always treat periodontal issues first.

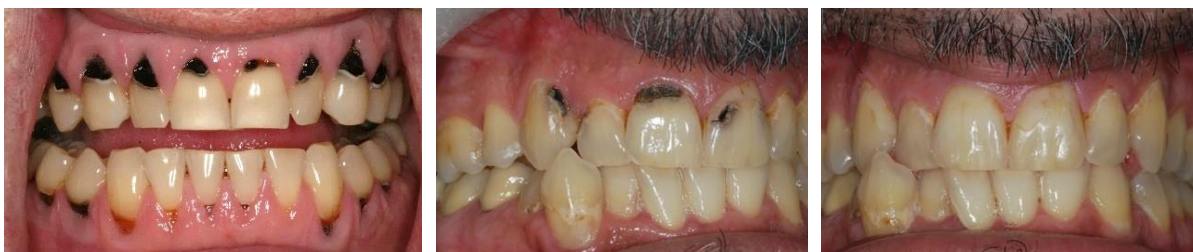

Example aesthetic cases

These photographs are just a few examples of the types of case you could submit. Further examples are provided at the end of this document.

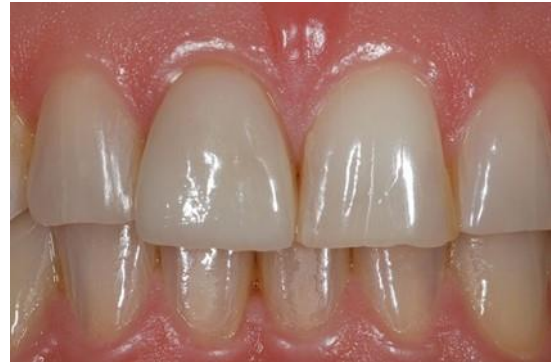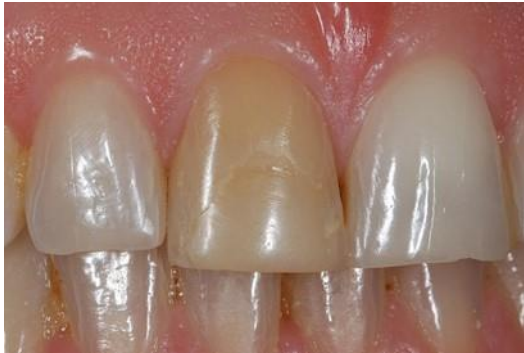CASE A

Treatment of caries



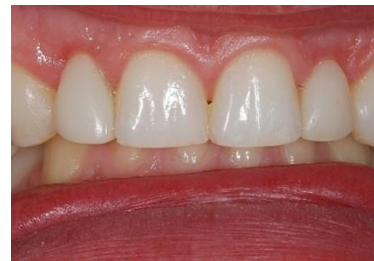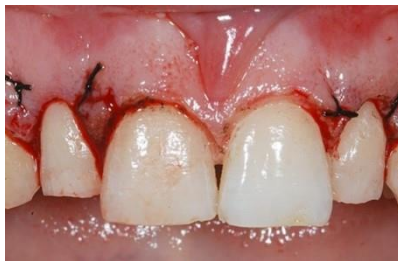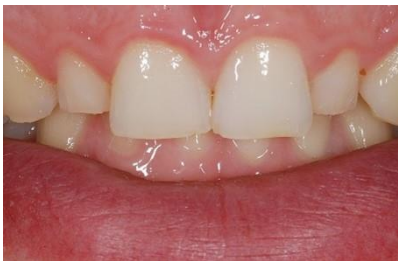CASE B

Internal/external bleaching and provision of a pressed lithium disilicate veneer



CASE C

Crown lengthening and provision of direct aesthetic composite veneers



More cases are shown at the end of this document.

PRESENTING YOUR FINAL CASE

Your final case should consist of case photographs that illustrate the treatment you carried out, supported by a short written clinical record. You should include pre-op, interim and post-op photographs.



TIP: judges will predominantly assess your case on the strength of your **photographs** and **reflection**, looking at your aesthetic dentistry skills, how your treatment has benefited your patient and what you have learnt from carrying out the case.

Save your case as a PDF, with your full name in the file name, and submit it to us on the CGDent website.



Submit your final case PDF here: cgdent.uk/tom-bereznicki-award-for-advanced-aesthetic-dentistry

Here is an outline of the sections you should include, indicating the word limits allocated. **We have also created an example of a final case for you to follow and a video that includes formatting tips (see below).**

CLINICAL RECORD

(Up to 600 words in total)

To include:

- **Presentation on initial visit:** initial complaint/history of clinical presentation
- **Relevant medical, dental, social history:** only include this if clinically relevant, otherwise N/A
- **Brief record of initial clinical presentation:** extra oral and intra oral – radiograph(s) only if clinically necessary
- **Brief description of initial treatment plan,** including an outline of any relevant treatment discussions with your patient
- **Pre-op photographs:**
 - A. Face on retracted AND non-retracted views.
 - B. Left lateral retracted AND non-retracted views.
 - C. Right lateral retracted AND non-retracted views.
 - D. Occlusal view of the arch(es) being treated.
 - E. Smile view.
 - F. Full face view (optional).
 - H. Pre-op dated radiographs, only if clinically necessary.
- **Interim photographs - NOT required unless there is something particularly unusual during the treatment phase**
- **Interim radiographs – ONLY if clinically necessary**

RECORD OF TREATMENT SEQUENCE

A written treatment record is not needed in most cases and should only be included for more complex cases (up to 250 words)

- **Post-op photographs**
 - The same format as pre-op photographs listed above
 - Include post-op radiographs, only if clinically necessary
- **Pre-op and post-op photographs positioned next to each other for comparison**



POST-OP PHOTOS TIP: as well as taking post-op photos immediately after treatment in case your patient does not return, we recommend that you also photograph your case **ONE WEEK** after treatment, to allow the teeth to rehydrate and look their best.

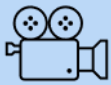
REFLECTION

(up to 250 words)

Include learnt experiences, problems you encountered and how you addressed them, what you have learnt and how you would have treated the case differently. If your patient refused the treatment you recommended, tell us about it here and how you adapted the treatment to suit the patient's requirements or financial restrictions. Or if it all went smoothly, just say so.

FINAL CASE SUBMISSION EXAMPLE AND GUIDANCE VIDEO

Here is an example of a final case for you to follow. It is important that you watch our guidance video for tips on how to format your case.



IMPORTANT: WATCH THIS VIDEO for final case formatting tips



Dr Tom Bereznicki
Dental Education Foundation

CGDent and GC Award for Foundation Trainees

DR FRED BLOGGS - CASE PRESENTATION EXAMPLE

CLINICAL RECORD ON PRESENTATION

- Pt presented – no pain
- Concerned with her gappy appearance
- Dislikes her midline gap - would like it closed
- Knows she was born without her two lateral incisors and would like the canines to look less pointy and more like normal front teeth
- Was unaware that her teeth may look larger than they are already if the spaces are closed

- Was not prepared to pay for a diagnostic wax up – but happy to proceed as she understands the procedure is additive and so the additions can be removed or modified if she does not like them

Discussed

- The choice of doing nothing – not acceptable to the patient
- Orthodontics – does not want to wear braces long term – she was told that it would involve moving canines which would be a slow prolonged treatment option – over a year
- Did not appreciate the tooth sized space left following orthodontics would require either a denture or an adhesive bridge – pt too young for implants as bone growth continues until around the age of 23 or so – implants submerging is a possibility
- Pt does not want a denture – has a friend who had an adhesive bridge that keeps coming off and does not one of these either

Further discussion – pt decided she would prefer composite space closure – does not want her teeth cut, so will not accept veneers. Appreciates composite could chip or discolour but is prepared to take that risk.

Discussed whitening –

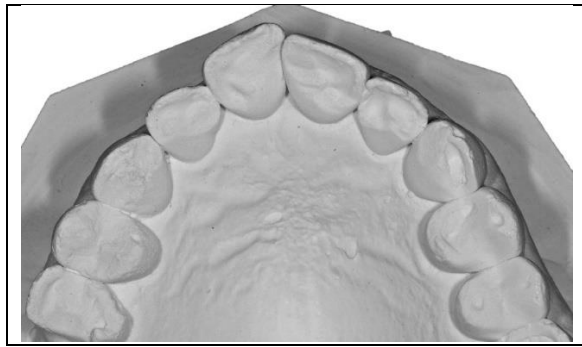
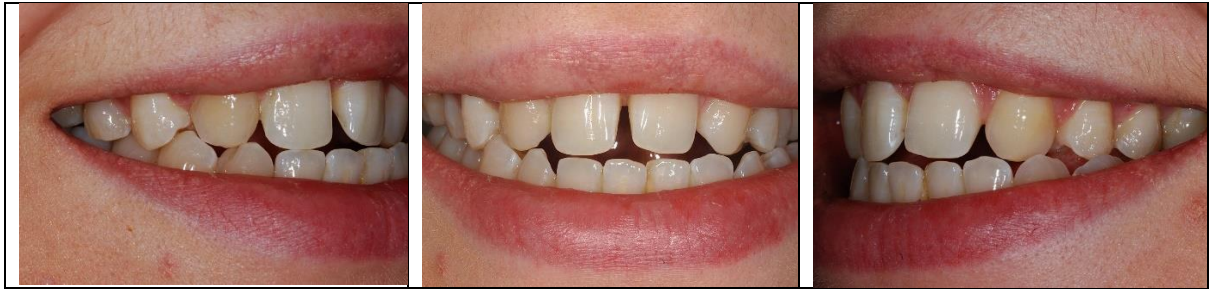- pt informed that if whitening is a possible choice at some point in the future, the composite will not change colour and so there would be a cost to re-veneer the space closures provided
- pt did not appreciate that composite cannot be whitened and would like to proceed with that first

Clinical observations – the patient has a mild anterior open bite so the prognosis of longevity is very good and chances of chipping very low – pt informed that eg opening packaging could cause debonding and replacement would be at the patient expense

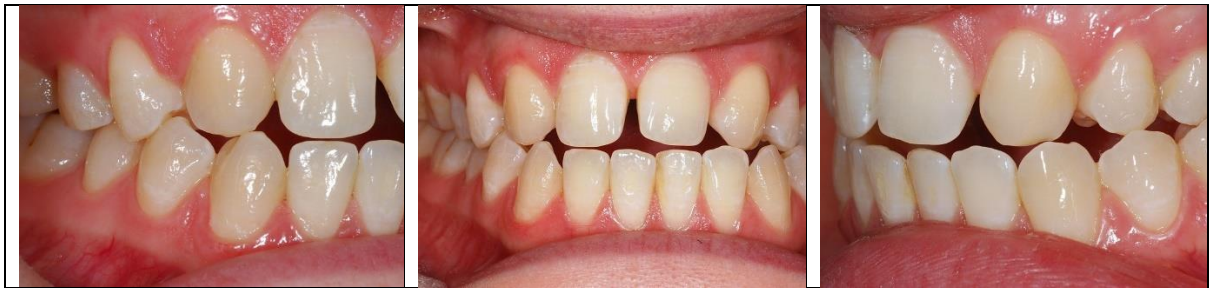Only other points you may feel are really pertinent to the case should be briefly included:

There were two possible treatment options to provide the same outcome for this case – freehand or diagnostic wax up and then using a putty stent. I chose to do this case freehand.

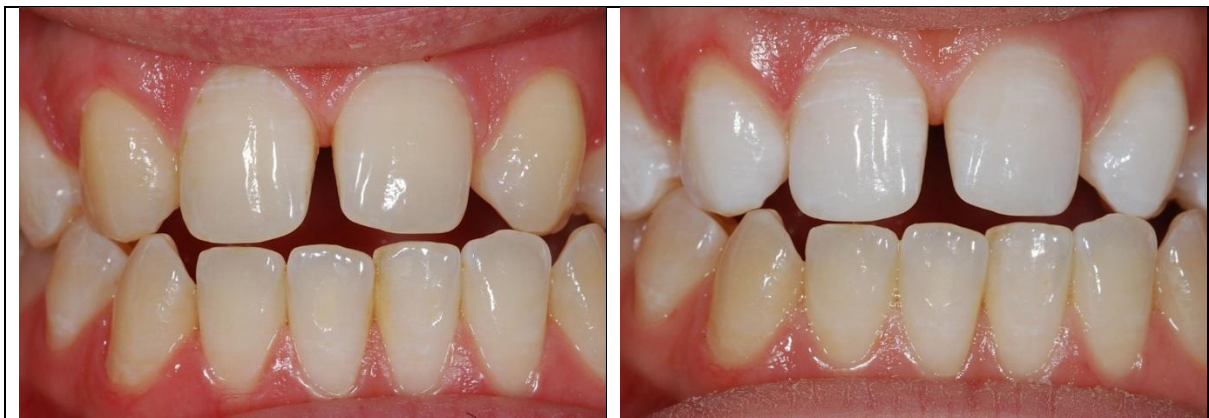Medical History, periodontal chartings etc are not required unless there are specific issues which you had to take into consideration as part of the treatment plan.



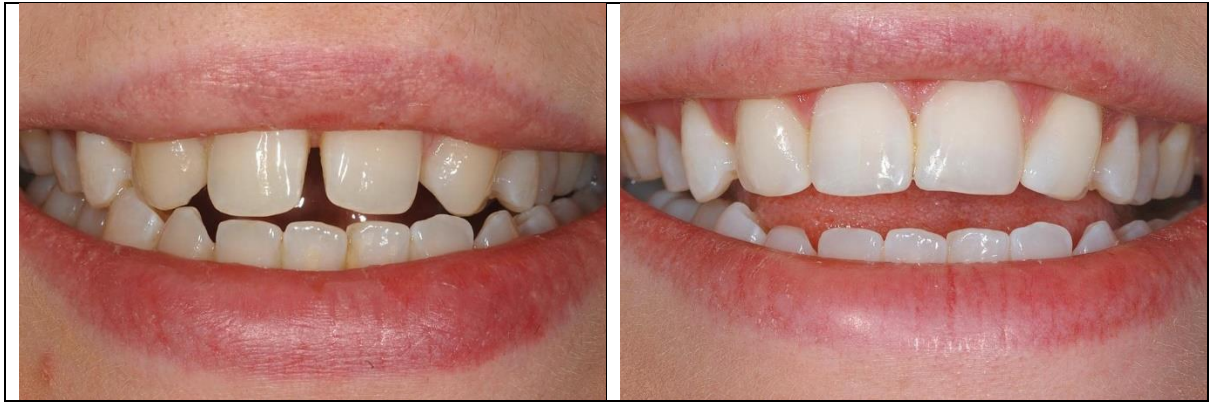Occlusal view of the arch being treated



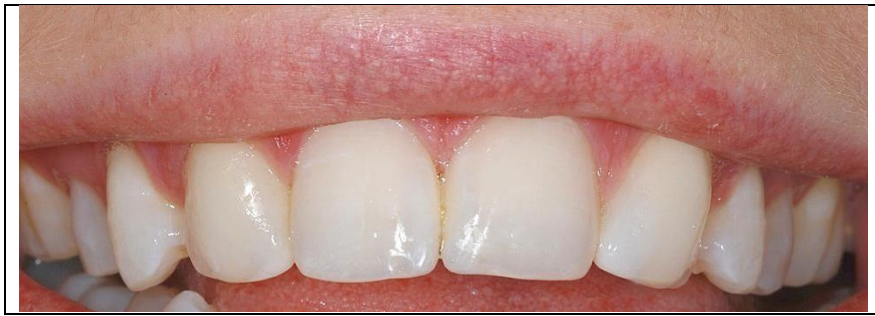Retracted view prior to treatment



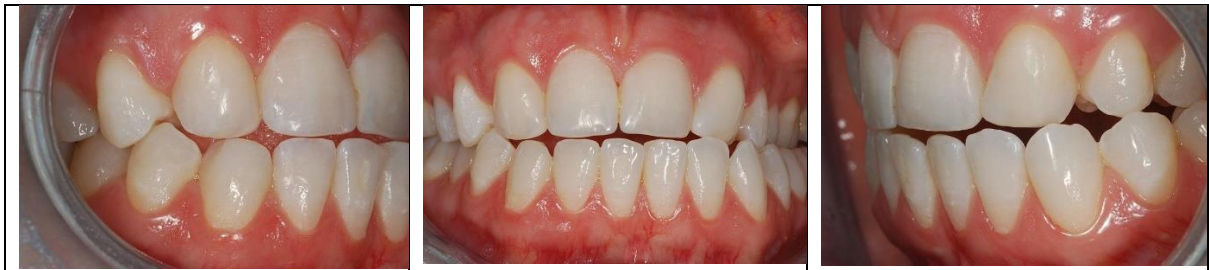Pre and post whitening



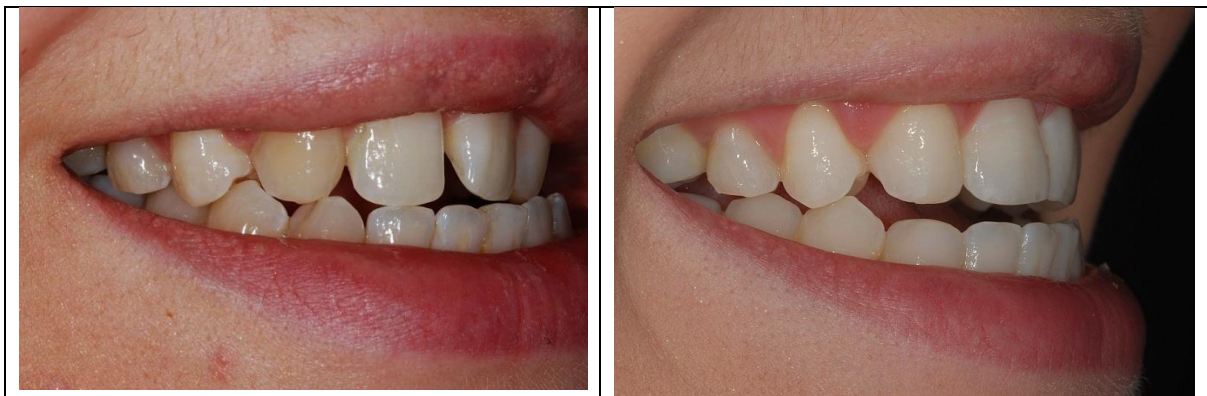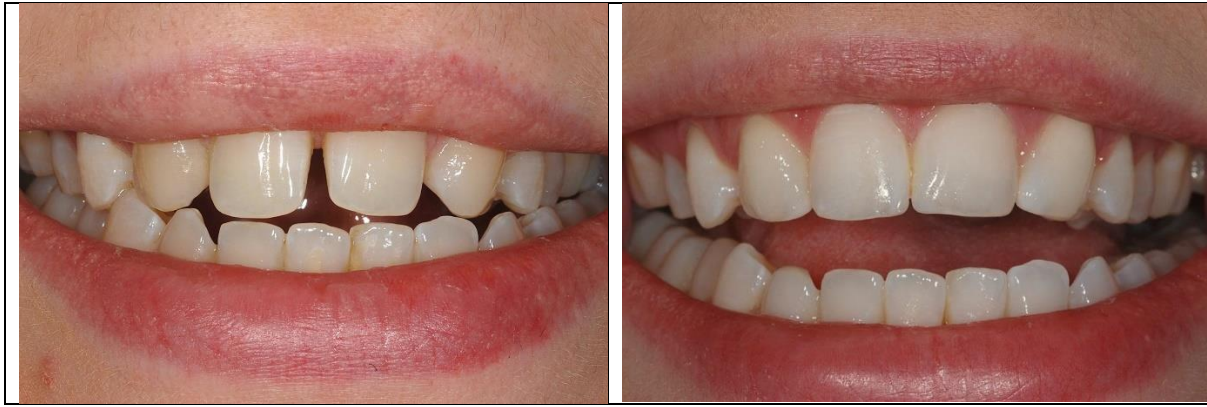Pre and post space closure



Close up view



Post op retracted view



Pre and post op views

REFLECTION

The Reflection is a key part of the case. In this section, you can write about what you have learnt by treating this case. Did you encounter any problems? How did you address them? How would you treat the case differently if you could do it again? If your patient refused the treatment you recommended, tell us about it here and how you adapted the treatment to suit the patient's requirements or financial restrictions. Or did it just go smoothly, in which case just say so.

SUCCESSFUL CANDIDATES

Entries will be assessed and scored based on the clinical skills and reflective skills demonstrated in each case and the 36 highest scoring entrants will be the award winners. Anyone who is unsuccessful in the competition can re-enter with a new case in subsequent years, subject to continued eligibility.



The successful candidates will be announced in October 2025.

The Judging panel comprises the Trustees of The Tom Bereznicki Charitable Educational Foundation and suitably qualified members of the College, and their decision is final. The Trustees of The Tom Bereznicki Charitable Educational Foundation represent the Foundation and the College of General Dentistry.

They will each receive a fully funded place on a two-day, hands-on digital dentistry course at the Dentsply Sirona Academy in Weybridge, Surrey. The prize includes UK travel costs (unless living locally), hotel accommodation and subsistence

The course has been specially designed for this award by Dr Tom Bereznicki and Dr Chris Leech, to provide early career dentists with a step-by-step introduction to digital dentistry techniques, and how harnessing them can enhance your aesthetic practice and patient care. The course is repeated on three dates, with 12 places allocated to each course date.

Participants will have access to pre-course training videos eg on the science of digital materials, and it is essential that they watch this prior to attending the hands-on course.



BEFORE ENTERING THE AWARD, ENSURE YOU ARE FREE TO ATTEND AT LEAST ONE OF THE COURSES.

- **Fri 14 – Sat 15 November 2025**
- **Fri 28 – Sat 29 November 2025**
- **January 2026 (date tbc)**

The course dates are non-transferable. Please put the dates in your calendar. If you are chosen as one of the winners and are not able to attend any of the course dates, your place may be given to another entrant.

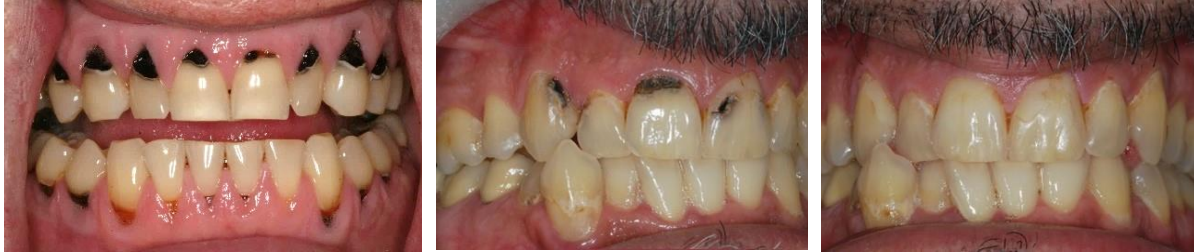When the course has been completed, winners will also receive a CPD certificate.

Scroll down to see more example cases.

ALL EXAMPLE CASES

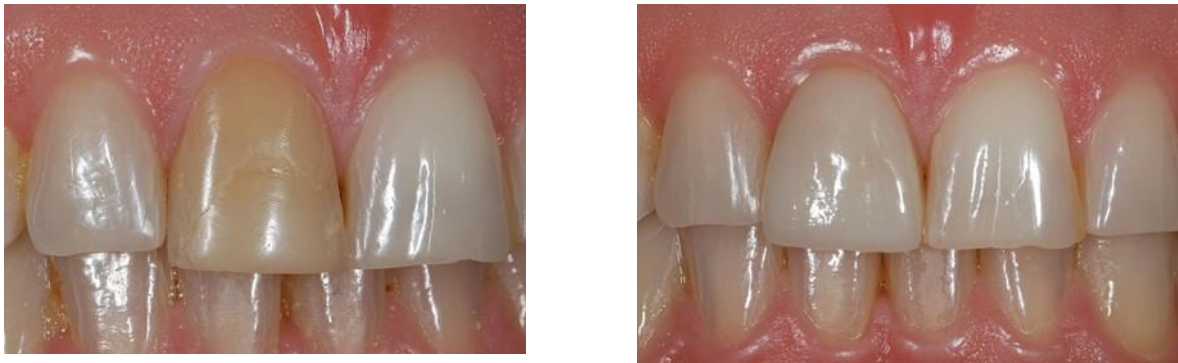CASE A

Treatment of caries



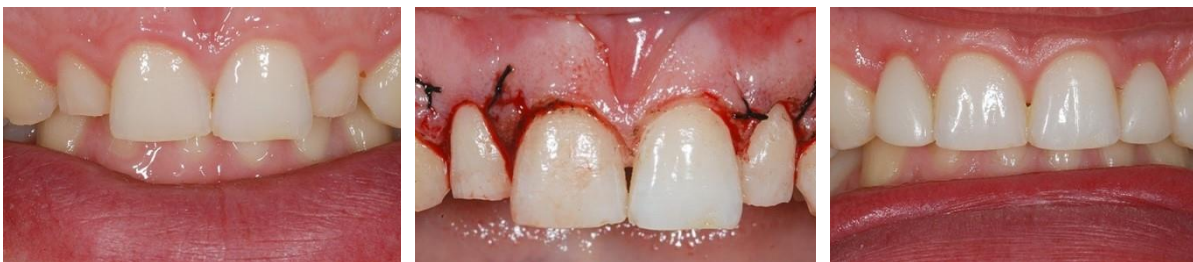CASE B

Internal/external bleaching and provision of a pressed lithium disilicate veneer



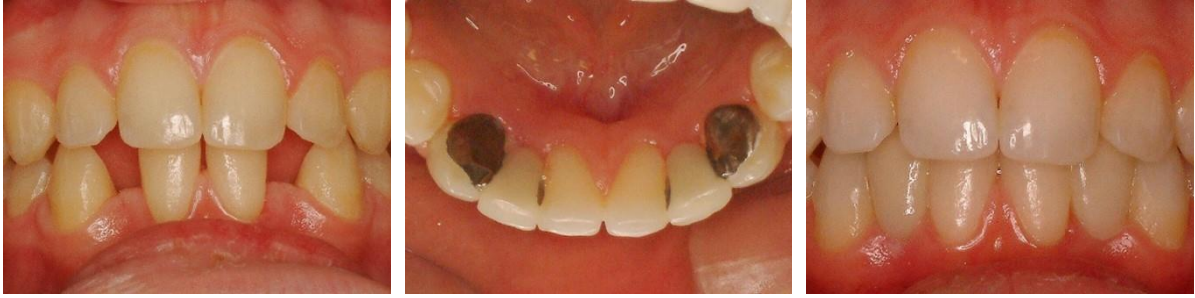CASE C

Crown lengthening and provision of direct aesthetic composite veneers



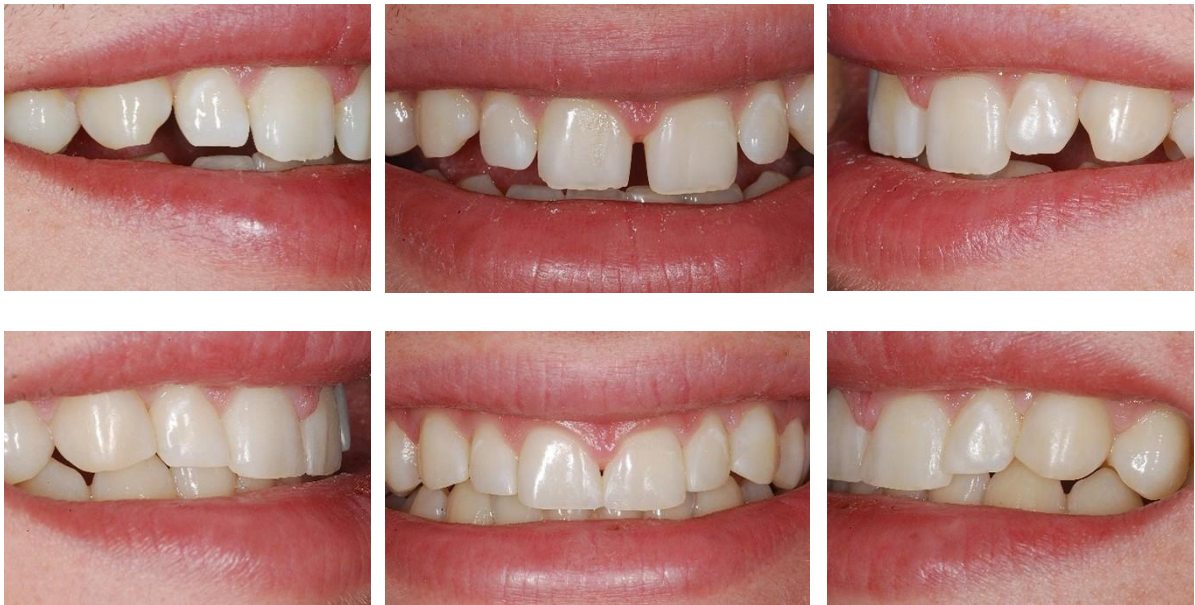CASE D

Adhesive bridgework replacing congenitally absent lateral incisors – ovate pontic form created to give an attractive emergence profile



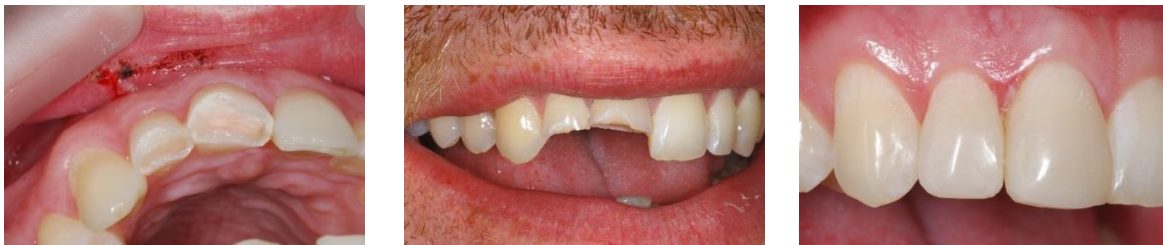CASE E

Whitening and composite space closure



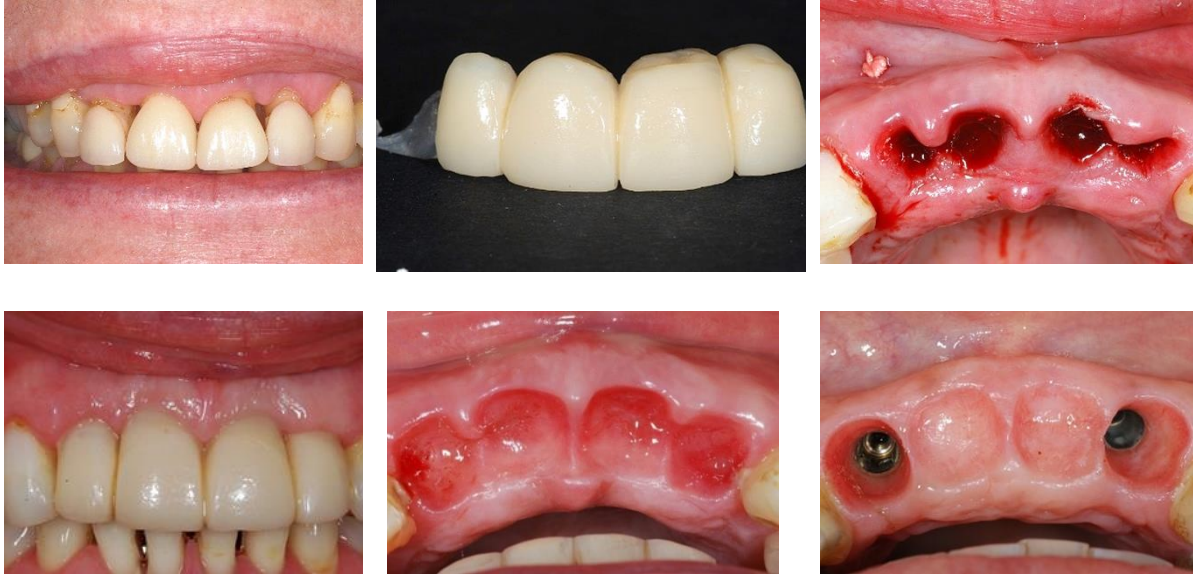
CASE F

Trauma case – RCT was deemed unnecessary at this point. Composite build ups



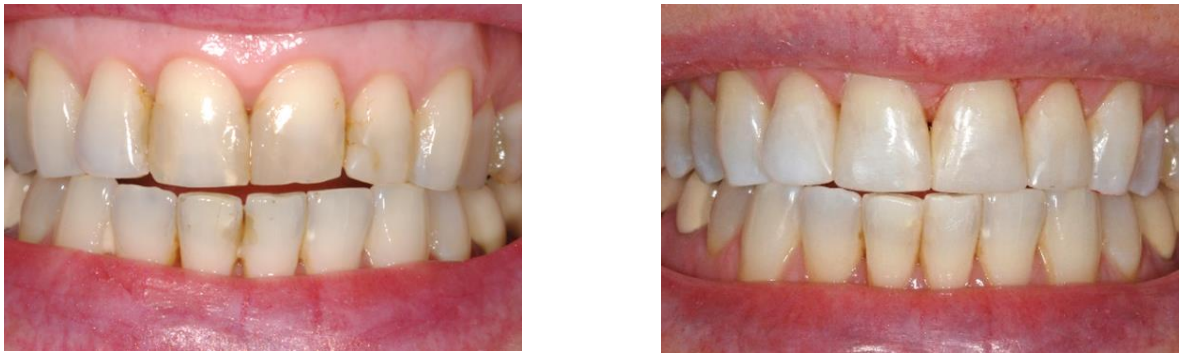CASE G

Use of a metal/composite adhesive bridge as an immediate temporary restoration – removed at intervals to develop the emergence profile by the addition of composite to the pontics. In turn this showed the implantologist exactly where the implants should be placed in the lateral incisor position to ensure optimal aesthetics.



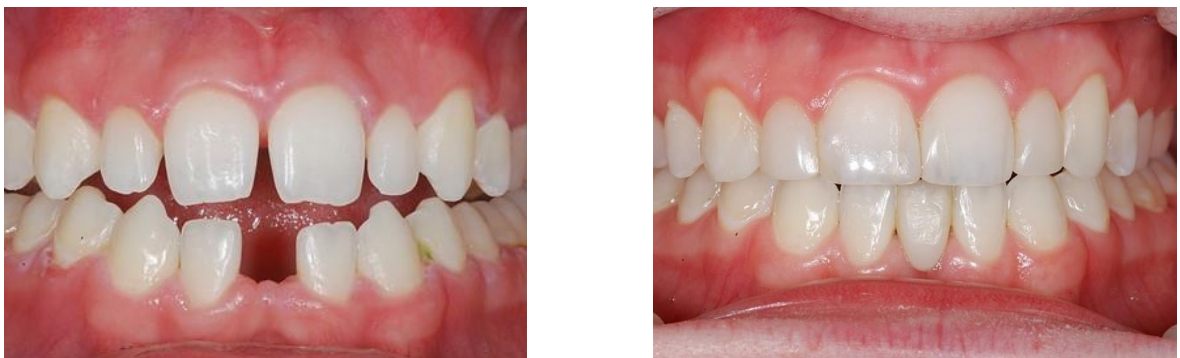CASE H

Re-layering old composites



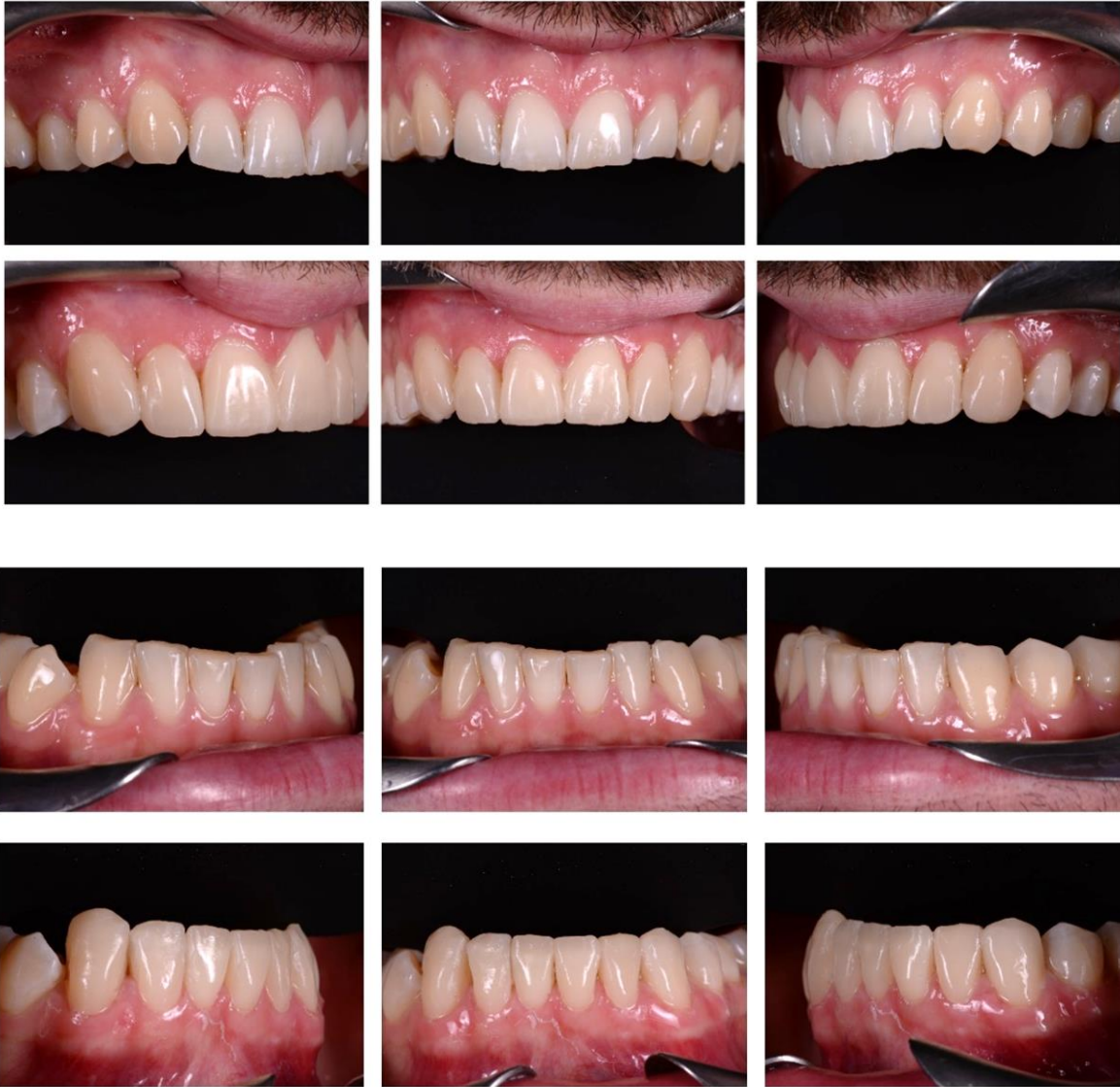CASE I

Composite midline space closure, composite veneers on lateral incisors and lower adhesive bridge



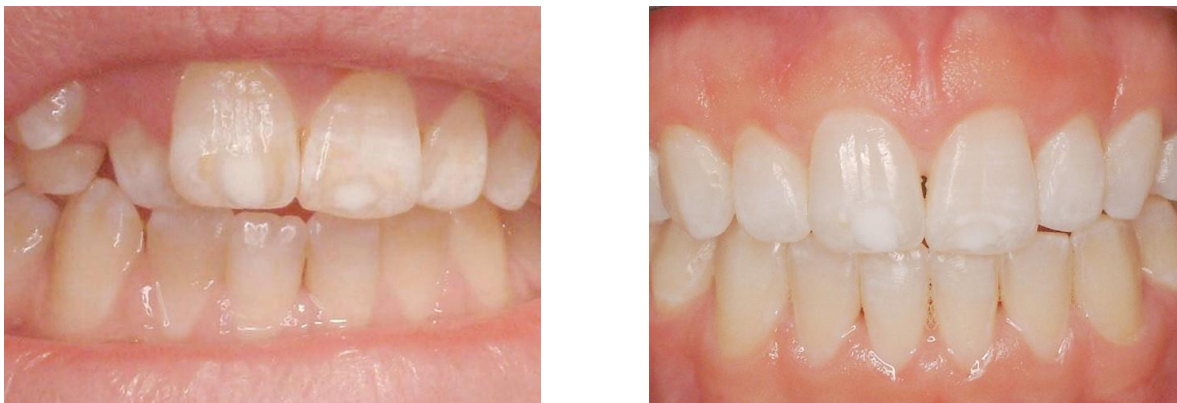CASE J

Wear Case



CASE K

Orthodontics and treatment of congenital hypocalcification enamel lesions



CASE L

Wear case

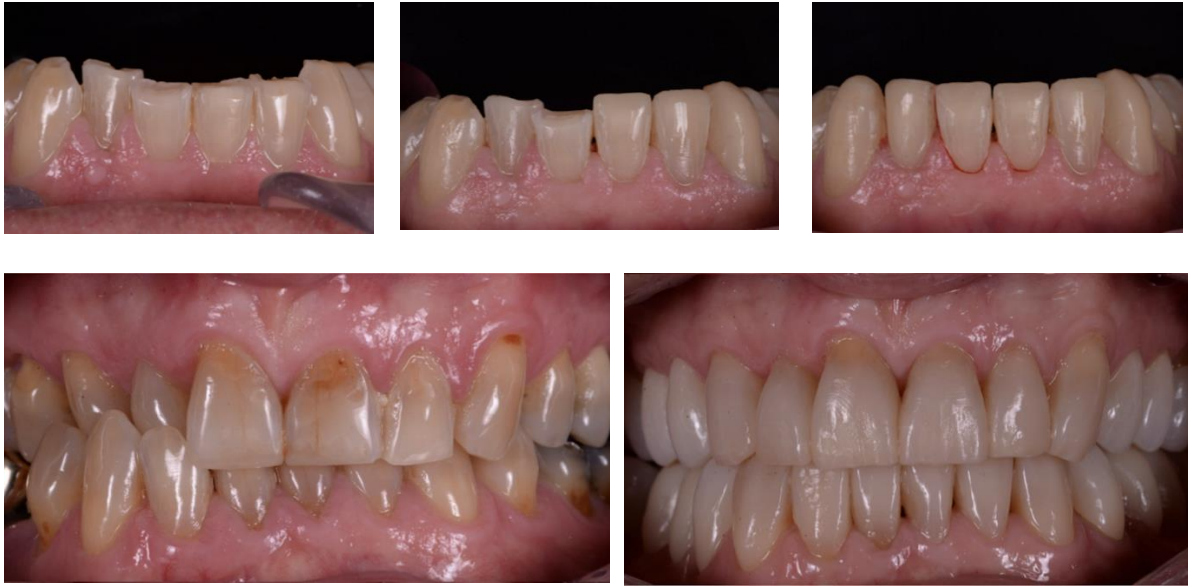

Photo credits: cases J & L courtesy of Dr Chris Leech; all other clinical cases courtesy of Dr Tom Bereznicki.

**The entry and submission deadlines have been extended and the course due to take place on 4-5 July 2025 has been rescheduled to early 2026 (date to be confirmed).*