

THE TOM BEREZNICKI AWARD FOR TOOTH WEAR CASES

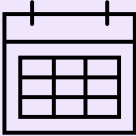
Developed in conjunction with CGDent and GC

ENTRY GUIDANCE 2026

The Award for Tooth Wear Cases is open to Dentists who qualified between **2020 to 2024**, and who practise in the UK. This is your opportunity to showcase your clinical skills, reflective skills and the high standard of care you provide to your patients.

To enter, you must submit a suitable case that you are **about to start treating**. You will find details on case criteria further in the guidance.

KEY DATES

	Initial entries close	Monday 10 August 2026
	Final cases submitted by	Monday 19 October 2026
	Winners announced by	End October 2026
	Injection Moulding course	Saturday 5 December 2026

HOW TO ENTER

1. Identify an appropriate case to enter the competition
 2. Complete our online entry form, including pre-op photos to ensure case eligibility
 3. Complete tooth wear treatment
 4. Submit your case
-
1. The first step is to identify a case that you would like to enter in the competition (see the **Case Eligibility Criteria**). Ensure you gain your patient's consent before you enter the competition. You will also need your patient's consent to **publish** their pre-op and post-op photos (mouth only) in professional publications including online, in the event that you are successful in the competition.
 2. Ready to enter? First [create a free College subscriber account](#) on the CGDent website or [sign in](#) to an existing account. Please **check your junk box** if you do not receive a confirmation email.



Create a free online account here: cgdent.uk/register-new
Or sign in here: cgdent.uk/login

Complete our online entry form and attach up to **twelve** pre-op photos of your case.

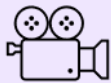
IMPORTANT For your case to be accepted into the competition, your photographs **MUST:**

- Be taken on a camera with the **correct date and time** settings.
- Be Jpg files, **max 1MB** each – larger file sizes can be included in your final case
- Correctly depict the clinical views as specified below:

- Face-on retracted AND non-retracted views – teeth in intercuspation.
- Left lateral retracted AND non-retracted views - teeth in intercuspation.
- Right lateral retracted AND non-retracted views – teeth in intercuspation.
- Right, left and protrusive guidance – retracted.
- Occlusal view of the arch(es) being treated.
- Smile view.
- Full face view (optional).

Photos that do not adhere to these criteria will not be accepted into the competition. **[Click here to see examples of photos that are NOT acceptable.](#)**

Check the **Presenting your Final Case** section for final case requirements to ensure you have all the pre-op photos you will need.



IMPORTANT: [WATCH THIS VIDEO](#) for tips on taking effective clinical photographs



Complete the online entry form here: <https://cgdent.uk/tom-bereznicki-award-for-a-tooth-wear-case/>

We will check the eligibility of your case and let you know if your case is valid to enter the competition.

We are accepting a maximum number of 100 entries and once that cap has been reached, the competition will close to initial entries.

If, after your initial entry, your patient fails to complete treatment or you find a case you would prefer to enter, you may contact us before the initial entry deadline of **Monday 10 August 2026** with new pre-op photographs, and we will confirm if the case is eligible. Please email us in the first instance at contact@cgdent.uk



The award closes for initial entries at 23:59 Monday 10 August 2026.

You may not change your case after this date, without exception.

3. Carry out the treatment on your patient.
4. Once completed, submit your case by the final entry date. Your case should be submitted as a PDF and include:
 - A. An outline of the patient's observations and expectations regarding their appearance as well as any other issues raised.
 - B. Short summary of the proposed treatment plan – include any occlusal issues you have identified.
 - C. Reflection.
 - D. Pre-op and post-op photographs, and radiographs **only** if appropriate.

You will find more details about compiling your final case below in the **Presenting Your Final Case** section, including an example of a final case and a guidance video.



Submit your final case PDF here: <https://cgdent.uk/tom-bereznicki-award-for-a-tooth-wear-case/>



You may submit your case as soon as you have completed it, but the final case submission deadline is 23:59 on Monday 19 October 2026.

Without exception, we will not accept individual requests for a deadline extension.

CASE ELIGIBILITY CRITERIA

Your case:

- must be the treatment for tooth wear which may or may not include erosion.
- must involve treatment for **at least** four anterior teeth.
- must involve the use of composite to restore teeth - **unless a tooth cannot be restored in composite in which case a crown is permissible.**
- may involve teeth on the upper or lower arches but treatment often involves the treatment of teeth on both arches. If wear is involved in both arches, then both have to be treated – that is to say the case cannot be half carried out and submitted.
- may be treated by hand or by the composite injection moulding technique.
- may include the provision of a few crowns but only in cases where the patient has existing crowns that need to be replaced as part of the treatment. **A case simply replacing multiple crowns will not be accepted unless the opposing arch is treated with composite**
- may include **restoration of** posterior teeth as part of the treatment plan but these restorations will not be included in the judging process.
- may include specific elements that have been undertaken by a specialist, for example crown lengthening or orthodontics – specify the details in the final case presentation.

The following treatments are eligible for entry. **See the example case photos further in this document.**

- Treatment of tooth wear.
- Treatment of tooth wear which includes an occlusal component.
- Treatment including aesthetic erosion.

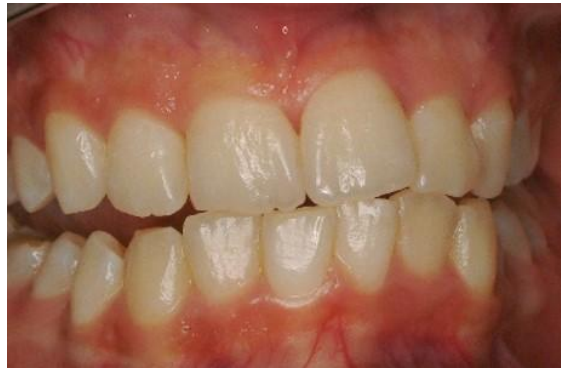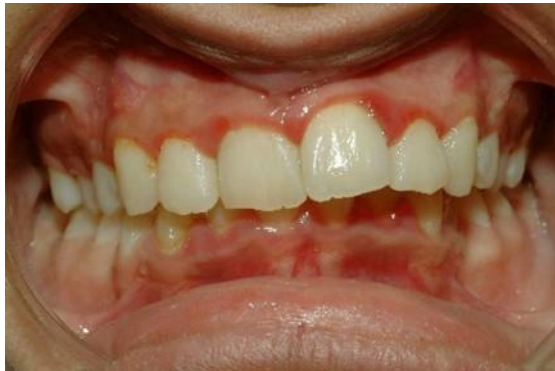Entrants will have at least ten weeks to complete the relevant part of the treatment.



PERIO TIP: in all cases, it is important to treat periodontal issues alongside the tooth wear treatment. Judges will expect to see a significant improvement in periodontal issues.

Example periodontal case

These photographs demonstrate the level of improvement we expect to see in cases which include periodontal issues.

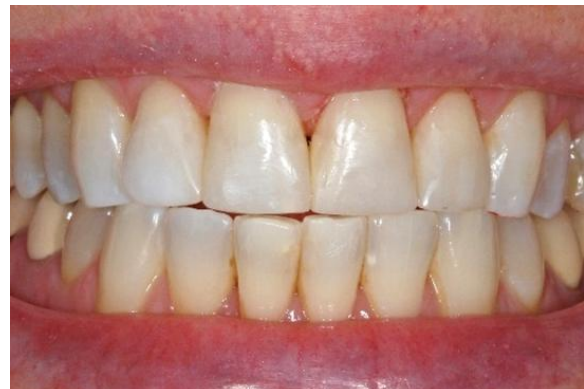
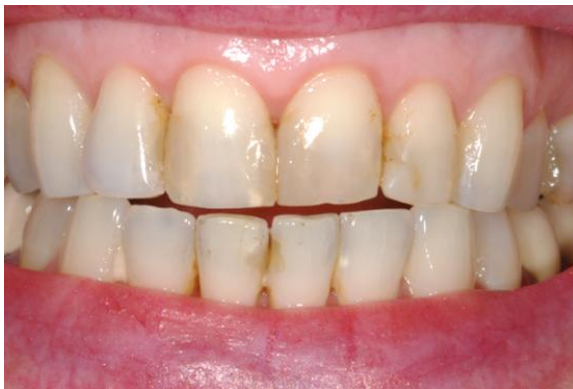
Example tooth wear cases

These photographs are just a few examples of the types of case you could submit. Further examples are provided at the end of this document.

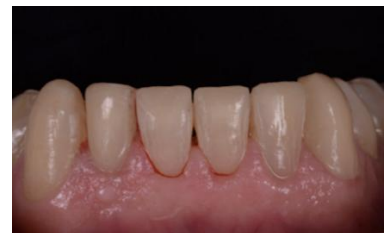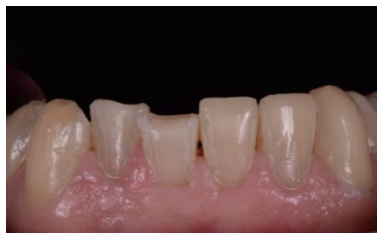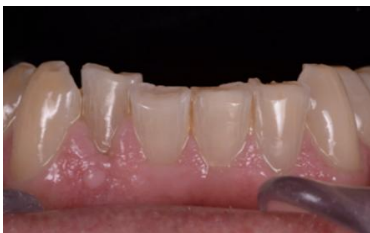CASE A

Re-layering old composites and introducing anterior guidance



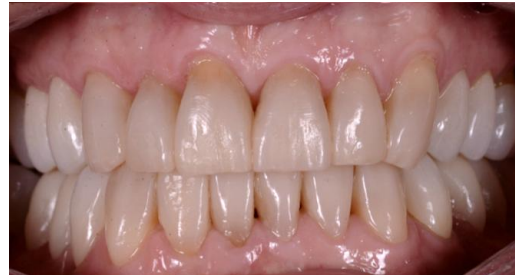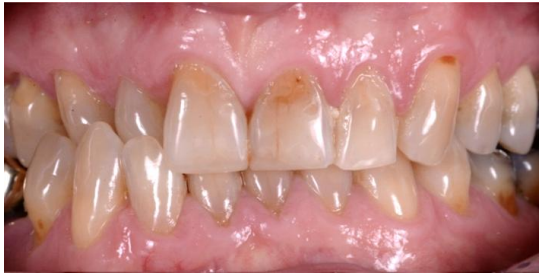CASE B

Wear case



CASE C

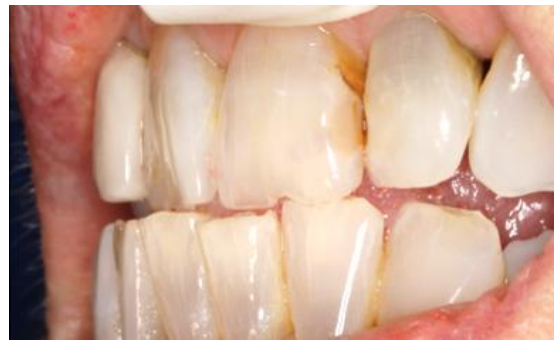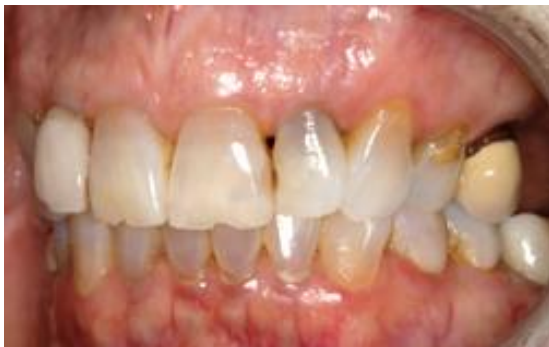Aesthetic wear case including orthodontics



Examples of occlusal issues involved in cases that need to be identified and treated as part of your submission

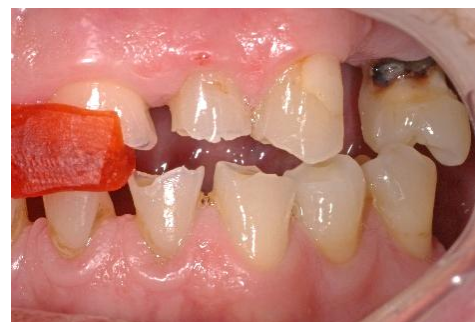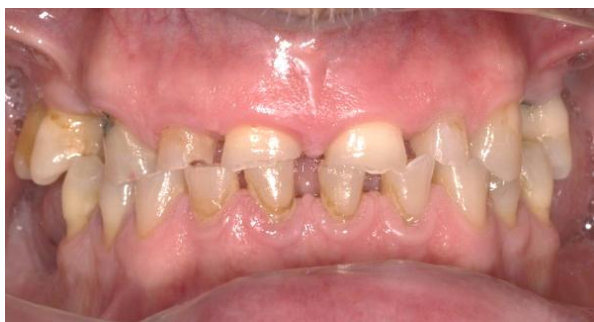CASE D

Incisal 'notches' created by parafunctional habits



CASE E

A case where ICP is not coincident with RCP



More cases are shown on page 10.

PRESENTING YOUR FINAL CASE

Your final case should consist of case photographs that illustrate the treatment you carried out, supported by a short written clinical record. You should include pre-op, interim, if appropriate to the case eg diagnostic intraoral mock-up, and post-op photographs.



TIP: judges will predominantly assess your case on the strength of your **photographs** and **reflection**, looking at your aesthetic dentistry skills, how your treatment has benefited your patient and what you have learnt from carrying out the case.

Save your case as a PDF, with your full name in the file name, and submit it to us on the CGDent website.



Submit your final case PDF here: <https://cgdent.uk/tom-bereznicki-award-for-a-tooth-wear-case/>

Here is an outline of the sections you should include, indicating the word limits allocated. **We have also created an example of a final case for you to follow and a video that includes formatting tips (see page 12).**

CLINICAL RECORD (Up to 600 words in total)

To include:

- **Presentation on initial visit:** initial complaint/history of clinical presentation
- **Relevant medical, dental, social history:** only include this if clinically relevant, otherwise N/A
- **Brief record of initial clinical presentation:** extra oral and intra oral – radiograph(s) only if clinically necessary
- **Brief description of initial treatment plan**, including an outline of any relevant treatment discussions with your patient
 - a. **Pre-op photographs:**
 - A. Face-on retracted AND non-retracted views – teeth in intercuspation.
 - B. Left lateral retracted AND non-retracted views - teeth in intercuspation.
 - C. Right lateral retracted AND non-retracted views – teeth in intercuspation.
 - D. Right, left and protrusive guidance – retracted.
 - E. Occlusal view of the arch(es) being treated.
 - F. Smile view.
 - G. Full face view (optional).

- **Interim photographs - NOT required unless there is something particularly unusual during the treatment phase such as a trial mock-up.**

Radiographs – ONLY if clinically and case pertinent necessary.

RECORD OF TREATMENT SEQUENCE

A written treatment record is not needed in most cases and should only be included for more complex cases (up to 250 words)

- **Post-op photographs**
 - The same format as pre-op photographs listed above
 - Include post-op radiographs, only if clinically necessary
- **Pre-op and post-op photographs positioned next to each other for comparison**



POST-OP PHOTOS TIP: as well as taking post-op photos immediately after treatment in case your patient does not return, we recommend that you also photograph your case **ONE WEEK** after treatment, to allow the teeth to rehydrate and look their best.

REFLECTION

(up to 250 words)

Include learnt experiences, problems you encountered and how you addressed them, what you have learnt and how you would have treated the case differently. If your patient refused the treatment you recommended, tell us about it here and how you adapted the treatment to suit the patient's requirements or financial restrictions. Or if it all went smoothly, just say so.



IMPORTANT: FINAL CASE SUBMISSION EXAMPLE AND GUIDANCE VIDEO
We have provided a final case report template on **page 12**, along with a link to a **guidance support video** with tips on formatting your report.

SUCCESSFUL CANDIDATES

Entries will be assessed and scored based on the clinical skills and reflective skills demonstrated in each case and the highest scoring entrants will be the award winners.

Anyone who is unsuccessful in the competition can re-enter with a new case in subsequent years, subject to continued eligibility.



The successful candidates will be announced in late October 2026.

The Judging panel comprises the Trustees of The Tom Bereznicki Charitable Educational Foundation and suitably qualified members of the College, and their decision is final. The Trustees of The Tom Bereznicki Charitable Educational Foundation represent the Foundation and the College of General Dentistry.

20 successful candidates will each receive a fully funded place on a one-day, hands-on Composite Injection Moulding Technique course at GC's training facility in the UK. The prize includes UK travel costs (unless living locally), hotel accommodation and subsistence and is worth around £1,000.

The course has been specially designed for this award by Dr Tom Bereznicki and Dr Chris Leech. Participants will learn how to successfully treat the challenges of aesthetic or wear cases using the latest injection moulding techniques, enhancing their aesthetic practice and patient care.



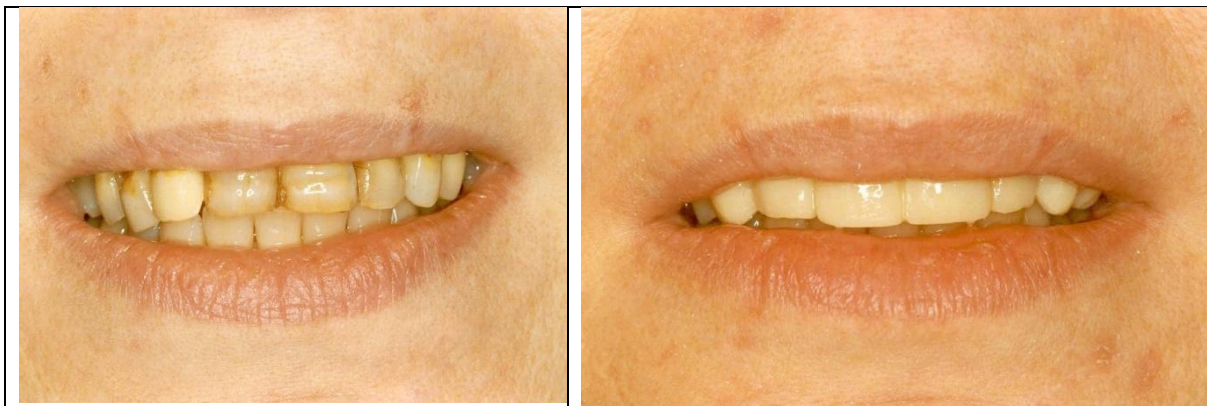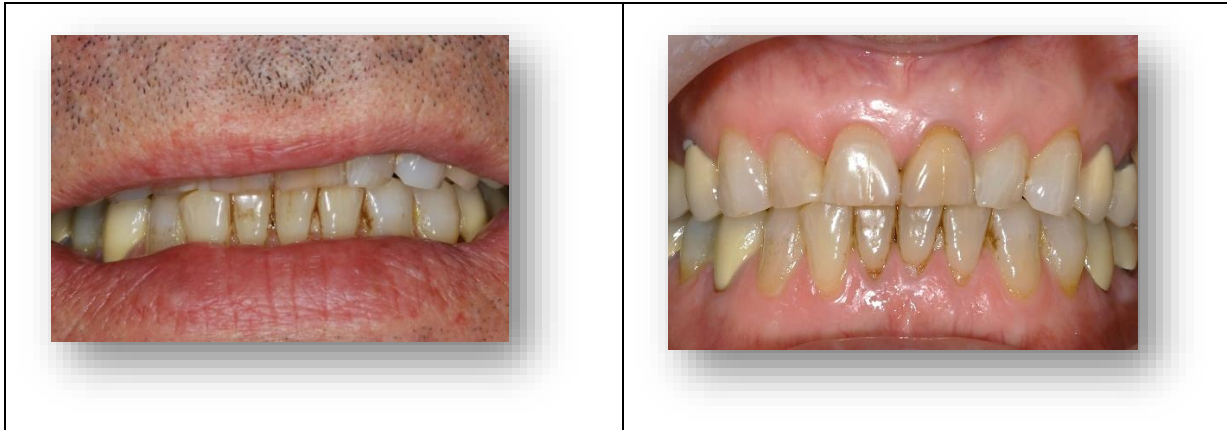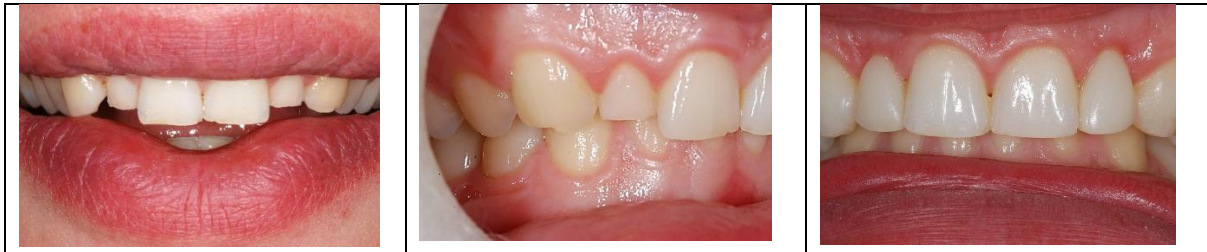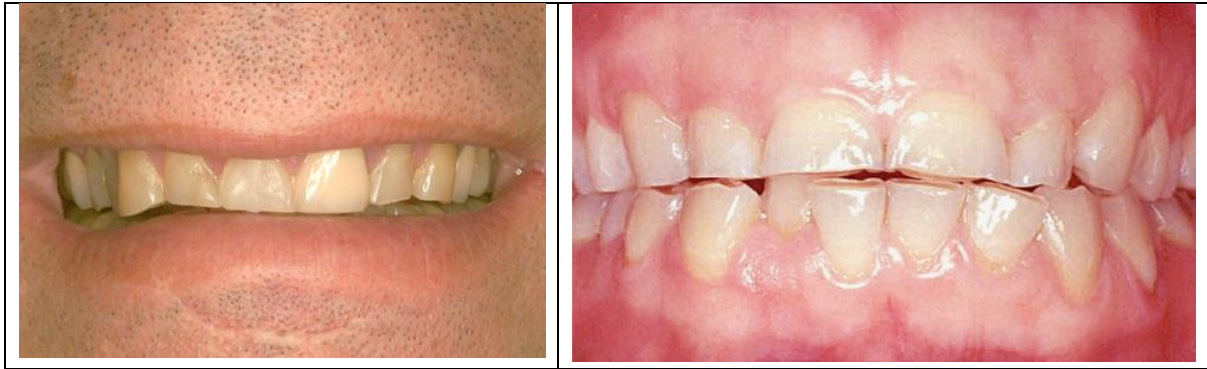BEFORE ENTERING THE AWARD, ENSURE YOU ARE FREE TO ATTEND THE COURSE ON SATURDAY 5 DECEMBER 2026

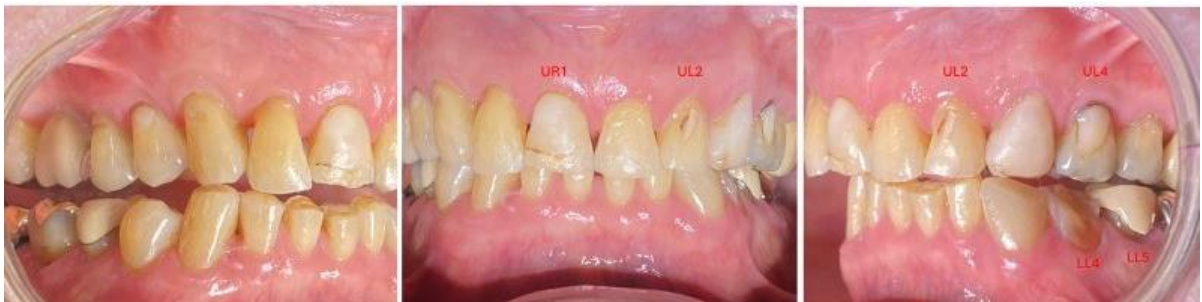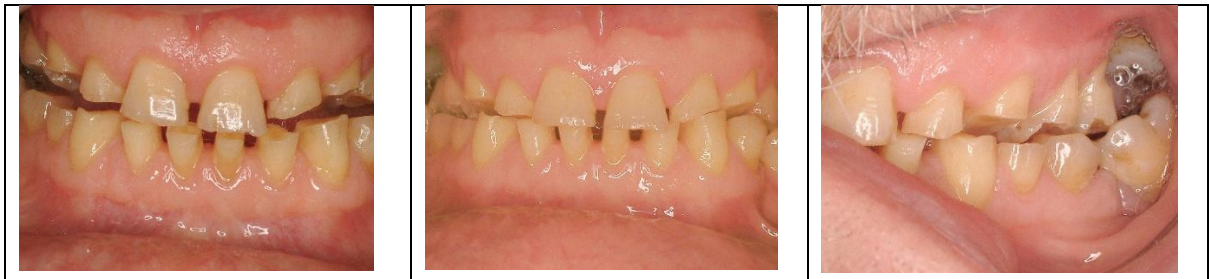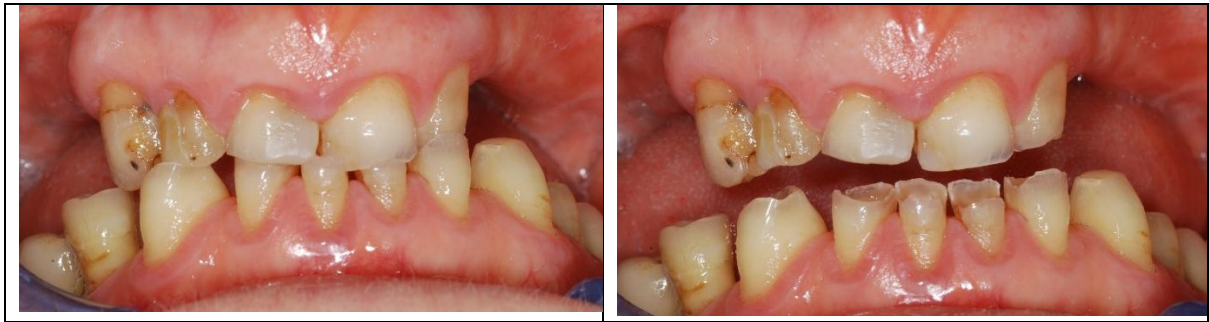The course date is non-transferable. Please put the date in your calendar. If you are chosen as one of the winners and are not able to attend the course, your place may be given to another entrant.

When the course has been completed, winners will also receive a CPD certificate.

Scroll down to see more example cases AND a final case report template.

EXAMPLE CASES



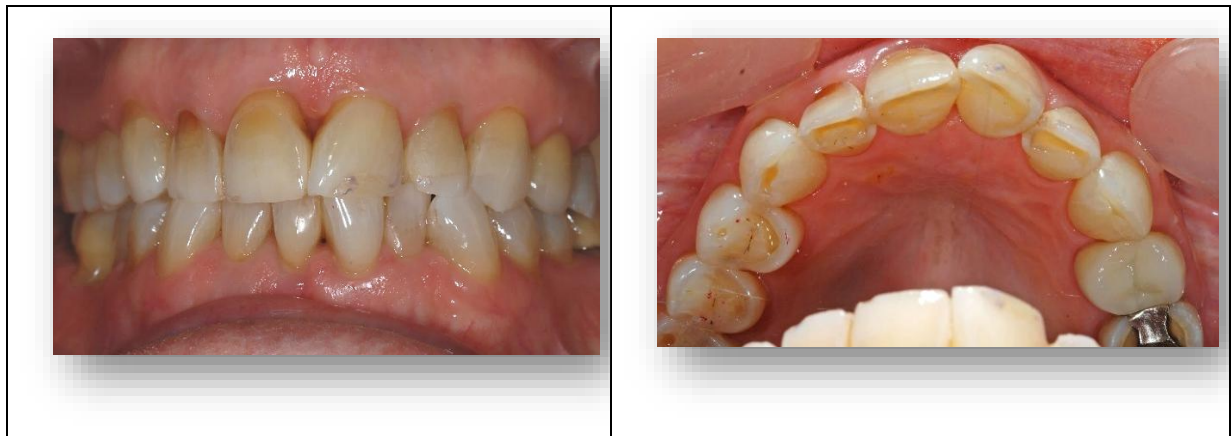
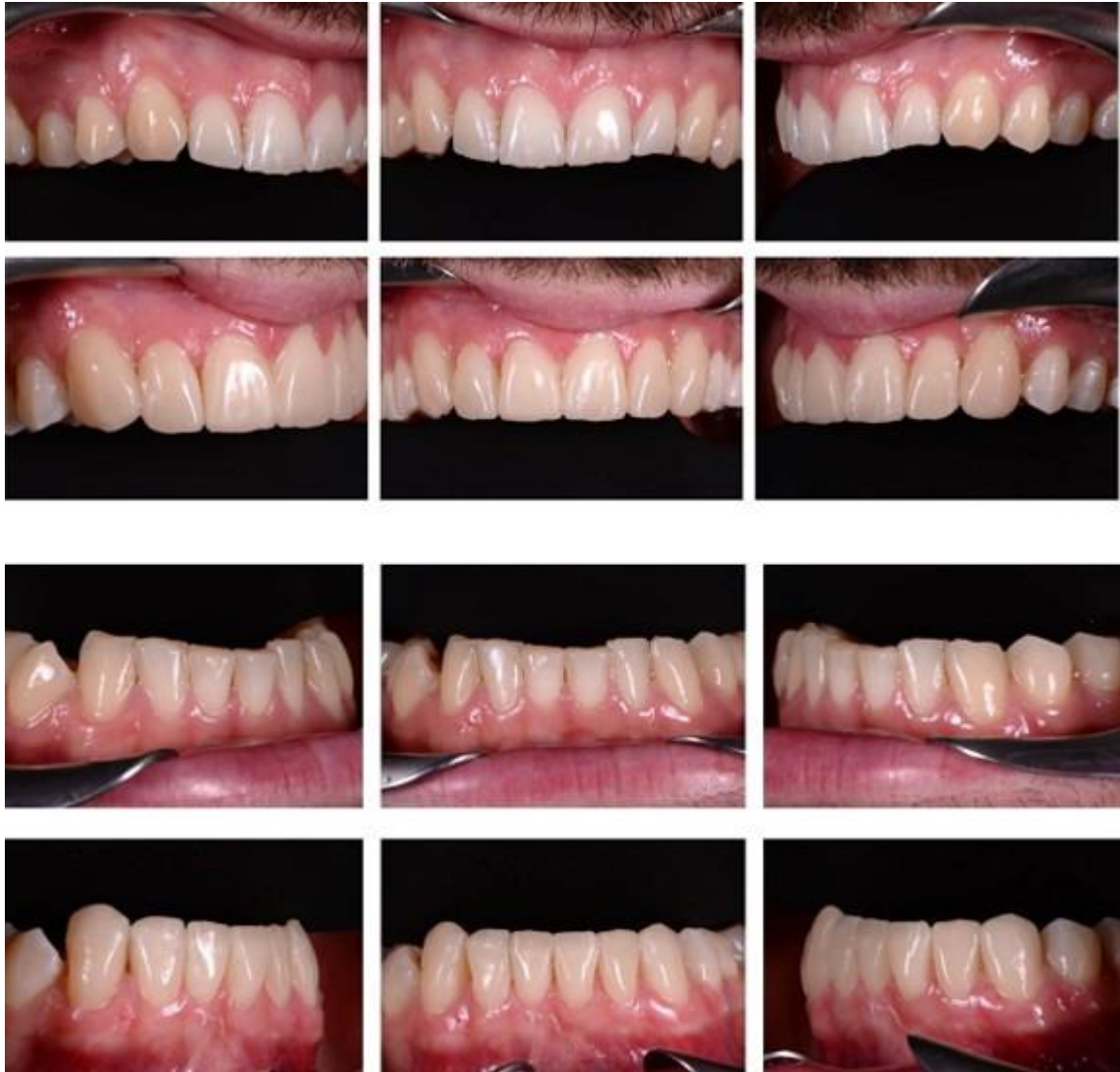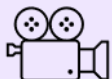




Photo credits: cases courtesy of Dr Tom Bereznicki, Dr Chris Leech and Dr Ronan Lee

FINAL CASE SUBMISSION EXAMPLE AND GUIDANCE VIDEO

Below is an example of a final case so you can follow the structure. The case featured is not a tooth wear case, but you can follow the layout and sections used here. It is important that you watch our guidance video for tips on how to format your case.



IMPORTANT: [WATCH THIS VIDEO](#) for final case formatting tips

DR FRED BLOGGS - CASE PRESENTATION EXAMPLE

CLINICAL RECORD ON PRESENTATION

- Pt presented – no pain
- Concerned with her gappy appearance
- Dislikes her midline gap - would like it closed
- Knows she was born without her two lateral incisors and would like the canines to look less pointy and more like normal front teeth
- Was unaware that her teeth may look larger than they are already if the spaces are closed
- Was not prepared to pay for a diagnostic wax up – but happy to proceed as she understands the procedure is additive and so the additions can be removed or modified if she does not like them

Discussed

- The choice of doing nothing – not acceptable to the patient
- Orthodontics – does not want to wear braces long term – she was told that it would involve moving canines which would be a slow prolonged treatment option – over a year
- Did not appreciate the tooth sized space left following orthodontics would require either a denture or an adhesive bridge – pt too young for implants as bone growth continues until around the age of 23 or so – implants submerging is a possibility
- Pt does not want a denture – has a friend who had an adhesive bridge that keeps coming off and does not one of these either

Further discussion – pt decided she would prefer composite space closure – does not want her teeth cut, so will not accept veneers. Appreciates composite could chip or discolour but is prepared to take that risk.

Discussed whitening –

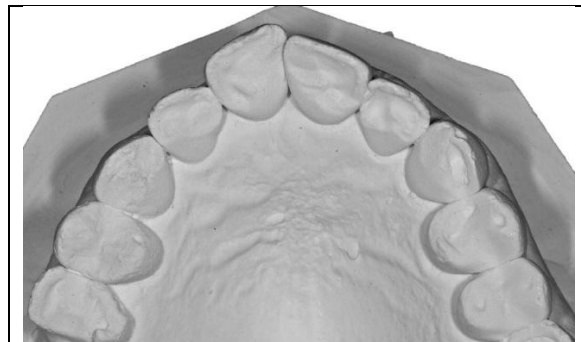
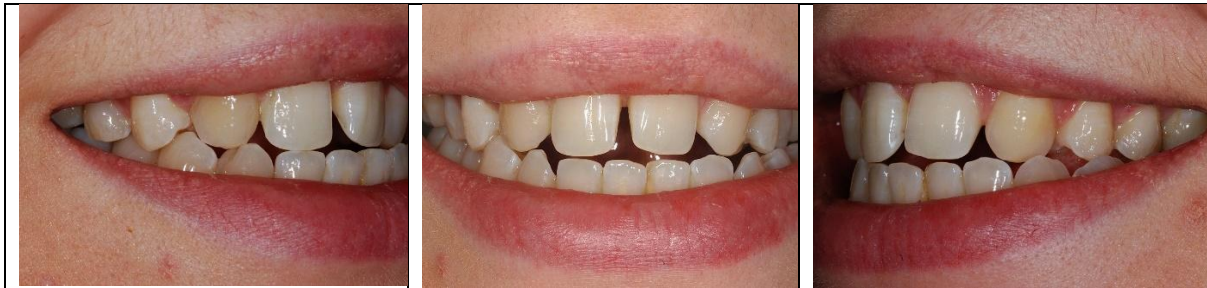- pt informed that if whitening is a possible choice at some point in the future, the composite will not change colour and so there would be a cost to re-veneer the space closures provided
- pt did not appreciate that composite cannot be whitened and would like to proceed with that first

Clinical observations – the patient has a mild anterior open bite so the prognosis of longevity is very good and chances of chipping very low – pt informed that eg opening packaging could cause debonding and replacement would be at the patient expense

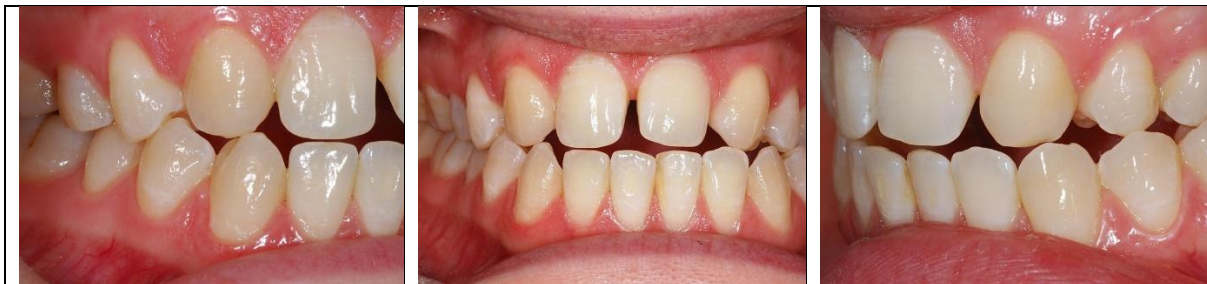Only other points you may feel are really pertinent to the case should be briefly included:

There were two possible treatment options to provide the same outcome for this case – freehand or diagnostic wax up and then using a putty stent. I chose to do this case freehand.

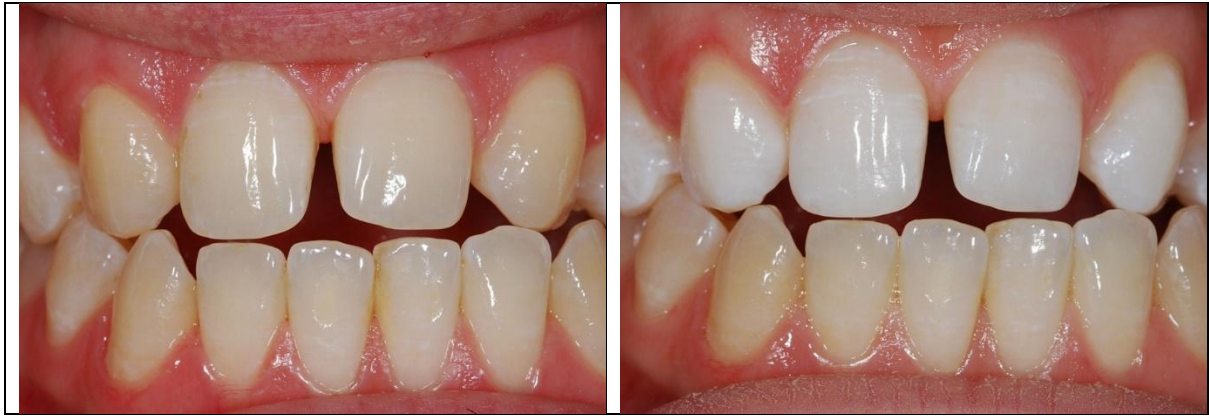Medical History, periodontal chartings etc are not required unless there are specific issues which you had to take into consideration as part of the treatment plan.



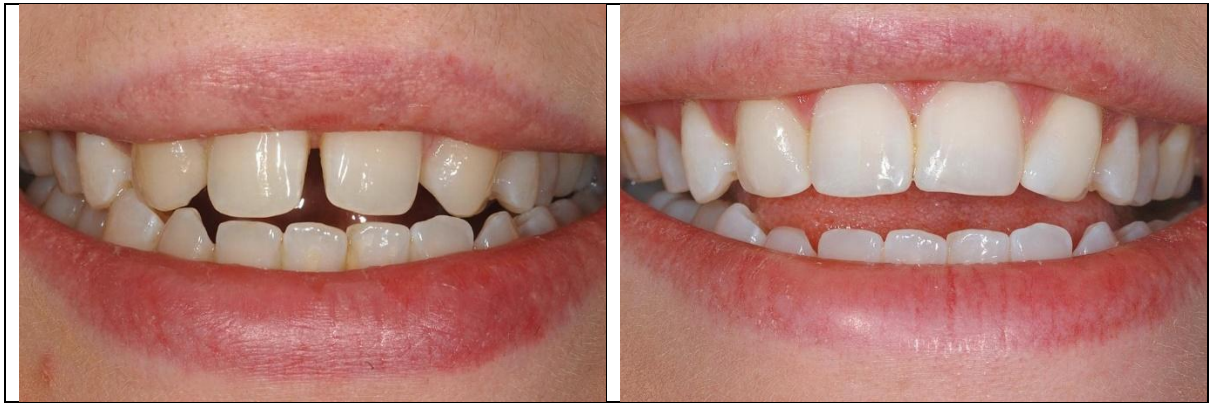Occlusal view of the arch being treated



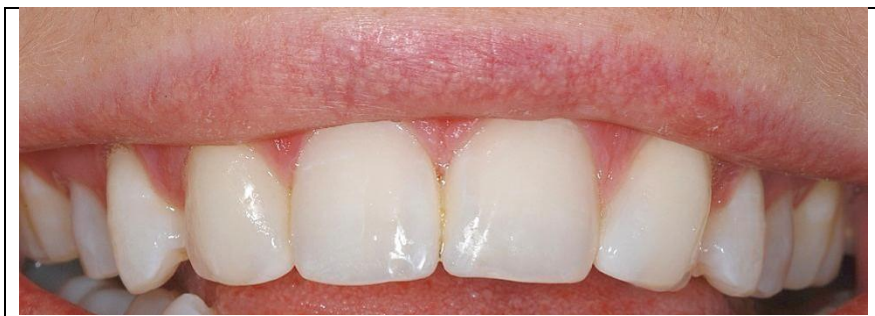Retracted view prior to treatment



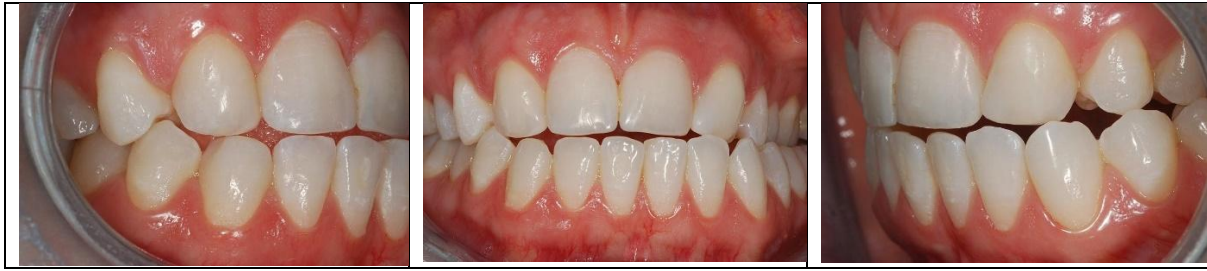Pre and post whitening



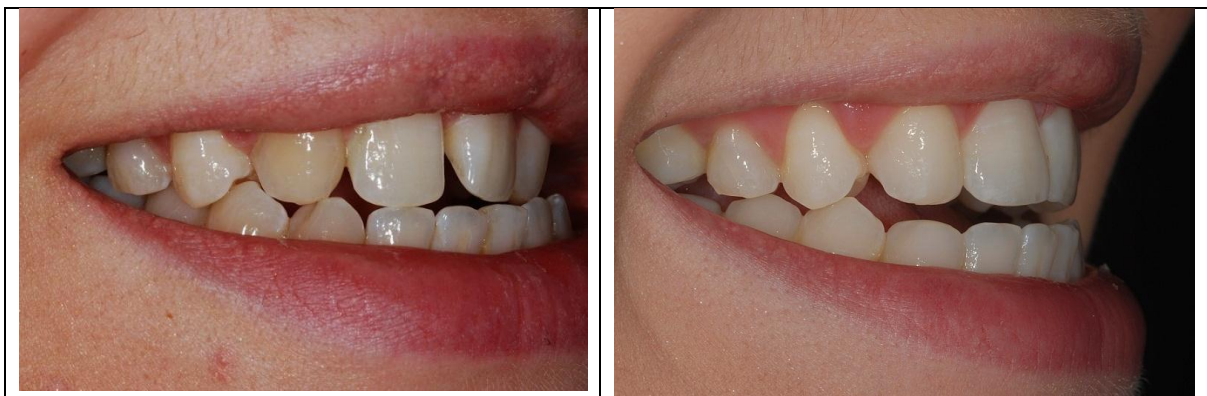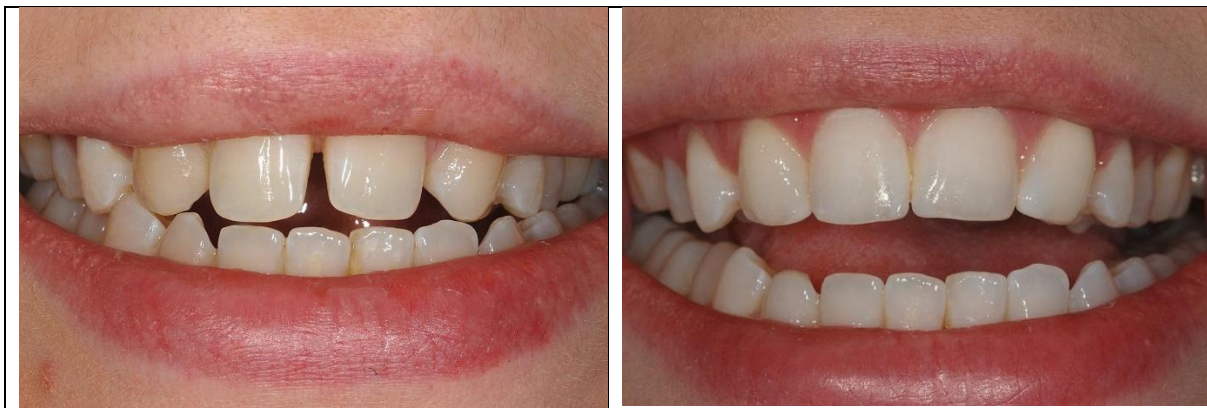Pre and post space closure



Close up view



Post op retracted view



Pre and post op views

REFLECTION

The Reflection is a key part of the case and a large number of points are allocated to it. In this section, you can write about what you have learnt by treating this case. Did you encounter any problems? How did you address them? How would you treat the case differently if you could do it again? If your patient refused the treatment you recommended, tell us about it here and how you adapted the treatment to suit the patient's requirements or financial restrictions. Or did it just go smoothly, in which case just say so.
