



Selection Criteria for Dental Radiography

updated 2018

Selection Criteria for Dental Radiography

3RD EDITION (UPDATED 2018)
EDITORS: K HORNER, K A EATON



Published by
Faculty of General Dental Practice (UK)
London

Email: fgdp@fgdp.org.uk
Website: www.fgdp.org.uk

Selection Criteria for Dental Radiography

THIRD EDITION (UPDATED 2018)

EDITORS: K HORNER, K A EATON

ISBN: 978-1-9999761-0-1

First edition published 1998
Second edition published 2004
Third edition published 2013 (reprinted 2015 and 2018)

© Faculty of General Dental Practice (UK) 2018
All rights reserved. No part of this publication may be reproduced, stored in a retrieval system or transmitted in any form or by any means, electronic, mechanical, photocopied, recorded or otherwise, without the prior written permission of the Faculty of General Dental Practice (UK).

While every effort has been made to ensure the accuracy of the information contained in this publication, no guarantee can be given that all errors and omissions have been excluded. The Faculty of General Dental Practice (UK) can accept no responsibility for loss occasioned to any person acting or refraining from action as a result of material in this publication.

All commercial product names carry the trademark of their manufacturer.

Production editors: Dave O'Malley, Justine Wallis, Amy Brewerton
Artwork/graphic design: Paul Woodcock, Herita MacDonald, Julie Brown, Mica Connelly & Darren Westlake at Smart Monkey Design
Print management: Hobbs

CONTENTS

FOREWORD	ix
ACKNOWLEDGEMENTS	xi
PREFACE TO THE THIRD EDITION	xv
1 INTRODUCTION	1
1.1 REMIT	1
1.2 JUSTIFICATION IN RADIOLOGY	1
1.3 WHY ARE GUIDELINES NEEDED?	2
1.4 WHAT ARE GUIDELINES?	3
1.5 WHY EVIDENCE-BASED GUIDELINES?	4
1.6 IMPLEMENTATION AND AUDIT	5
1.7 REVIEW OF GUIDELINES	5
1.8 UNDERSTANDING THE GUIDELINES	6
1.9 GUIDELINE METHODOLOGY	6
1.10 GAPS IN THE EVIDENCE	8
1.11 OVERVIEW OF RECOMMENDATIONS	8
1.12 REFERENCES	9
2 USE OF IONISING RADIATION	11
2.1 RADIATION DOSES AND RISKS IN DENTAL PRACTICE	11
2.1.1 <i>Introduction</i>	11
2.1.2 <i>Radiation damage</i>	11
2.1.3 <i>Radiation dose</i>	13
2.1.4 <i>Factors influencing effective dose</i>	14
2.1.5 <i>The risks</i>	17

CONTENTS

2.1.6	<i>Diagnostic reference levels</i>	19
2.1.7	<i>Doses and risks in context</i>	20
2.2	THE USE OF PANORAMIC RADIOGRAPHY	21
2.2.1	<i>The new patient to the practice</i>	22
2.2.2	<i>The endentulous patient</i>	23
2.2.3	<i>The orthodontic patient</i>	23
2.2.4	<i>Prior to oral surgery</i>	24
2.2.5	<i>Trauma</i>	24
2.2.6	<i>Temporomandibular joint problems</i>	25
2.2.7	<i>Conclusions</i>	25
2.3	REFERENCES	27
3	RADIOGRAPHS IN THE MANAGEMENT OF THE DEVELOPING DENTITION	33
3.1	INTRODUCTION	33
3.2	EARLY MIXED DENTITION	34
3.2.1	<i>Upper labial segment</i>	34
3.2.2	<i>Lower labial segment</i>	36
3.2.3	<i>Posterior segments</i>	37
3.3	LATE MIXED DENTITION	38
3.3.1	<i>Labial segments</i>	38
3.3.2	<i>Canines</i>	38
3.3.3	<i>Deciduous molars</i>	39
3.3.4	<i>Permanent molars</i>	40
3.4	ORTHODONTIC TREATMENT	41
3.5	REFERENCES	41
4	RADIOGRAPHS IN DENTAL CARIES DIAGNOSIS	43
4.1	INTRODUCTION	43
4.2	CHILDREN	44
4.2.1	<i>Caries risk assessment</i>	45

CONTENTS

4.2.2 <i>High caries risk</i>	46
4.2.3 <i>Moderate caries risk</i>	47
4.2.4 <i>Low caries risk</i>	48
4.3 ADULTS	49
4.3.1 <i>High caries risk</i>	51
4.3.2 <i>Moderate caries risk</i>	51
4.3.3 <i>Low caries risk</i>	51
4.4 DIGITAL DENTAL RADIOGRAPHY	52
4.5 NEWER RADIOGRAPHIC METHODS AND ALTERNATIVES TO RADIOGRAPHS FOR CARIES DIAGNOSIS	52
4.5.1 <i>Cone beam computed tomography</i>	52
4.5.2 <i>Elective temporary tooth separation</i>	53
4.5.3 <i>Fibreoptic transillumination</i>	54
4.5.4 <i>Electrical methods of caries diagnosis</i>	55
4.5.5 <i>Laser fluorescence methods</i>	56
4.5.6 <i>Quantitative laser fluorescence</i>	56
4.6 REFERENCES	57
4A. ALTERNATIVE APPROACH TO RADIOGRAPHY FOR CARIES DIAGNOSIS IN CHILDREN	61
4A.1 THE EAPD APPROACH	61
4A.2 REFERENCES	63
5 RADIOGRAPHS IN PERIODONTAL ASSESSMENT	65
5.1 INTRODUCTION	65
5.2 RECOMMENDATIONS	66
5.3 REFERENCES	69
6 RADIOGRAPHS IN ENDODONTICS	71
6.1 INTRODUCTION	71
6.2 ENDODONTIC DIAGNOSIS	71

CONTENTS

6.3	ROOT CANAL TREATMENT PLANNING	72
6.3.1	<i>Non-surgical root canal treatment</i>	73
6.3.2	<i>Surgical root canal treatment</i>	74
6.4	ROOT CANAL TREATMENT	74
6.4.1	<i>Electronic apex locators</i>	75
6.5	ENDODONTIC FOLLOW-UP	77
6.6	OTHER ENDODONTIC TREATMENTS	79
6.6.1	<i>Vital pulp procedures</i>	79
6.6.2	<i>Dental trauma</i>	79
6.7	CONE BEAM COMPUTED TOMOGRAPHY	80
6.8	REFERENCES	83
7	RADIOGRAPHS IN IMPLANT DENTISTRY	85
7.1	INTRODUCTION	85
7.2	REVIEW OF RADIOLOGICAL TECHNIQUES	87
7.2.1	<i>Periapical radiography</i>	88
7.2.2	<i>Occlusal radiography</i>	89
7.2.3	<i>Panoramic radiography</i>	89
7.2.4	<i>Lateral cephalometric radiography</i>	90
7.2.5	<i>Conventional cross-sectional tomography</i>	90
7.2.6	<i>X-ray computed tomography</i>	91
7.2.7	<i>Cone beam computed tomography</i>	91
7.2.8	<i>Magnetic resonance imaging</i>	94
7.3	CHOICE OF TECHNIQUES	95
7.4	REFERENCES	96
8	IMAGING STRATEGY FOR THE ADULT PATIENT	99
8.1	INTRODUCTION	99
8.2	THE NEW ADULT PATIENT	100

CONTENTS


8.2.1 <i>Panoramic radiography</i>	100
8.2.2 <i>Cone beam computed tomography</i>	100
8.3 SPECIFIC CLINICAL SITUATIONS	102
8.3.1 <i>Extraction of teeth</i>	102
8.3.2 <i>Heavily restored teeth</i>	103
8.3.3 <i>Toothwear</i>	104
8.3.4 <i>Radiographs for the estimation of endodontic working length</i>	104
8.4 LONG-TERM REVIEW AND MAINTENANCE	105
8.4.1 <i>Periodontal</i>	105
8.4.2 <i>Caries</i>	105
8.4.3 <i>Endodontic follow-up radiographs</i>	106
8.4.4 <i>Dental implants</i>	106
8.5 REFERENCES	106
9 GOOD PRACTICE	109
9.1 DO'S AND DON'TS	109
9.1.1 <i>Do</i>	109
9.1.2 <i>Don't</i>	110
9.2 IDEAS FOR AUDIT: DEVELOPING LOCAL GUIDELINES	111
9.2.1 <i>An audit to measure the quality of radiographs compared with NRPB guidelines</i>	111
9.2.2 <i>Setting a standard</i>	112
9.2.3 <i>Involving all team members</i>	113
9.2.4 <i>Gathering data</i>	113
9.2.5 <i>Comparing standards</i>	115
9.2.6 <i>Formulating an action plan</i>	116
9.2.7 <i>Audits involving teamwork in dental radiography</i>	116
9.3 MORE AUDIT IDEAS	119
9.4 REFERENCES	120

DEAN'S FOREWORD

Since our foundation in 1992, the Faculty of General Dental Practice (UK) has endeavoured to improve standards in primary dental care. Our standards and evidence-based guidelines (such as this current edition of *Selection Criteria for Dental Radiography*) are a core element of our work in this respect. This document, and our other standards publications, have become recognised within the profession as authoritative statements of good practice.

Technological advances in dental radiography since the 2004 edition mean that the third edition represents a re-write rather than an update.* In particular, there is improved advice on digital radiography and new guidance on cone beam CT scanning.

I would like to express my appreciation on behalf of the Faculty to all who have contributed to the production of this edition. It is my belief that this timely publication will prove invaluable to the profession.



Trevor Ferguson

Dean, FGDP(UK)

*The 2018 update includes changes as a result of the Ionising Radiation (Medical Exposure) Regulations 2017 and the Ionising Radiations Regulations 2017.

REVIEW EDITORS

Keith Horner PhD, MSc, BDS, Odont Dr (*hc*), FRCR, FDS, DDR
Professor of Oral and Maxillofacial Imaging, University of Manchester.
Honorary Consultant Dental Radiologist, Manchester University NHS
Foundation Trust.

Kenneth A. Eaton PhD, MSc, BDS, DHC, FFGDP(UK), FFPH, FHEA, FICD, MGDS
Visiting Professor, University College London, Eastman and King's College
London Dental Institutes.
Honorary Professor, University of Kent. Member of the Board of the FGDP(UK).

ACKNOWLEDGEMENTS

The editors would like to thank everyone who contributed to the first edition (1998) and to the second edition (2004). There were a large number of contributors, and they have laid the foundations for this third edition. Special thanks are due to those who have revised or rewritten sections in this third edition. Their names appear at top of the first page of each section.

The driving force behind the first edition was Malcolm Pendlebury. It was published during his term as the third Dean of the FGDP(UK), and his inspirational leadership saw the development of other Faculty standards publications. The work he carried

out, together with a Faculty Expert Panel chaired by Professor Nigel Pitts, has stood the test of time and given the FGDP(UK) a clear direction for the future.

The editors and the FGDP(UK) would like to thank the following people for their invaluable input in the development of this book.

Nicholas Drage
Crawford Gray
Peter Heasman
Keith Isaacson
Richard Palmer
Shanon Patel
Nigel Pitts
David Ricketts
Vivian Rushton
William Saunders
Ann Shearer
Andrew Shelley
Allan Thom
Andy Toy
Aradhna Tugnait
Anne Walker
Eric Whaites

The Faculty is also indebted to the following organisations, who provided feedback on the final draft of this book:

Associate Chief Dental Officer, Scottish Government
British Association of Oral and Maxillofacial Surgeons
British Dental Association
British Orthodontic Society
British Society of Dental and Maxillofacial Radiology
Committee of Postgraduate Dental Deans and Directors

Dental Protection Limited
Public Health England
Royal College of Physicians and Surgeons of Glasgow
Society and College of Radiographers
The Society for Radiological Protection

PRODUCTION TEAM

Dave O'Malley
Justine Wallis
Paul Woodcock
Charlotte Worker
Gareth Kingston
Jamie Woodward
Amy Brewerton
Smart Monkey Design

PREFACE TO THE THIRD EDITION

The Faculty of General Dental Practice (UK) has a commitment to improving the standards of patient care through the provision of standards publications and guidelines. Standards and guidelines are simply tools which a practitioner may use to improve treatment planning and care outcomes.

Since the second edition was published in 2004, new evidence and research findings have been published. There is now far wider use of digital radiography in dental practices, and cone beam computed tomography has progressed significantly. In particular, since the previous edition the European Commission has published three new relevant sets of guidelines: *Radiation Protection 136. European Guidelines on Radiation Protection in Dental Radiology*, *Radiation Protection 162. Criteria for Acceptability of Medical Radiological Equipment used in Diagnostic Radiology, Nuclear Medicine and Radiotherapy* and *Radiation Protection 172. Cone Beam CT for Dental and Maxillofacial Radiology: Evidence Based Guidelines*.[†]

Another development since 2004 is the addition of dental radiography to the General Dental Council's core topics for continuing professional development for all registrants (both dentists and dental care professionals).

The guidelines in this publication are based on the best available evidence. However, in a number of areas the level of the evidence is still poor and based on expert opinion. On occasion, there is therefore no one imaging strategy that can be supported with good-quality evidence, and expert opinion differs. This constraint is described further in the introduction that follows this preface.

However, the editors wish to stress that while the contents of this publication are based on the best available scientific knowledge, they set out guidelines for what is currently accepted as good practice and, as such, should not be considered to be prescriptive in all clinical circumstances.

Keith Horner and **Kenneth Eaton**

†This edition of *Selection Criteria for Dental Radiography* was updated in January 2018 to account for the introduction of the Ionising Radiations Regulations 2017 and the Ionising Radiation (Medical Exposure) Regulations 2017.

1.1 REMIT

These guidelines result from the work of an expert panel convened by the Faculty of General Dental Practitioners (UK) in 1994 on the recommendation that “an expert group should be set up to formulate selection criteria for dental radiology”.¹ This led to the production of two previous editions of this document, in 1998 and 2004.

The remit for the current edition is:

“To produce selection criteria which are specific to dental radiography. These criteria should encompass all aspects of radiological practice in dentistry, with a focus on primary dental care”.

1.2 JUSTIFICATION IN RADIOLOGY

X-ray exposure involves a risk to the patient. It is essential that any x-ray examination should show a potential net benefit to the patient, weighing the total diagnostic benefits it produces against the detriment that the exposure might cause. The efficacy, benefits and risk of available alternative techniques should be taken into account. This decision-making process is called ‘justification’ and is both an ethical² and a legal requirement.³

In order for the justification process to be carried out properly, it is essential that selection of dental radiographs is based on the individual patient’s history and a clinical examination. The routine use of x-rays for diagnosis based on a generalised approach rather than individual prescription is unacceptable. A ‘routine’ (or ‘screening’) examination is one in which a radiograph is taken regardless of the presence or absence of clinical signs and symptoms.

Choosing a radiograph for a patient should also be based upon consideration of the prevalence of diseases, their rates of progression and the diagnostic accuracy of the imaging technique. Furthermore, where decisions are made with patients to expose (or not to expose) a radiograph which may ultimately be contentious, a record should be made of that discussion and decision in the notes. For example, when looking at orthodontic cases, if the decision is not to expose a child to x-rays in the general practice, leaving that decision to the specialist on referral, it is crucial that the records demonstrate that. Frequently dentists are criticised for failing to identify, for example, ectopic teeth. Equally, in pregnancy, evidence of the patient's agreement to a particular course of action to take (or not take) a radiograph avoids later criticism.

It should be noted that under the regulations,³ justification should include consideration of exposures to “carers and comforters”. In a dental context this would mean, for example, a parent supporting a child undergoing an x-ray examination. The regulations suggest considering this person during the justification of the x-ray examination and considering the dose that they might receive and gaining informed consent.

1.3 WHY ARE GUIDELINES NEEDED?

A useful diagnostic investigation is one where the result – positive or negative – will alter or add confidence to a clinician's diagnosis and/or treatment planning. This is particularly important when x-rays are involved. At present, there is wide variation in practice as to which radiographs are exposed in primary dental care, and when. There is a need to minimise¹ and/or prevent radiographic examinations:

- Where the results are unlikely to affect patient management and/or prognosis.
- That are repeated unnecessarily.
- That duplicate those taken previously.
- That are inappropriate.
- Where avoidable lapses in quality assurance impact upon patient dose and care.

There is also a need to ensure that radiographic information contributes to achieving optimal standards of diagnosis and patient care, and that clinically significant disease is not missed. This may mean that some operators should undertake more radiographic examinations while others should undertake fewer, depending upon the

needs of their individual patients, following history taking and clinical examination. For example, in endodontics, the use of periapical radiographs taken from different angulations may facilitate an understanding of the root canal system, while for patients with ongoing evidence of low caries risk, less frequent bitewing radiographs may be needed.

It is a legal requirement that those using x-rays on patients are adequately trained,³ particularly when adopting new techniques (such as panoramic radiography or cone beam computed tomography). Guidelines such as these can provide a useful contribution to training.

1.4 WHAT ARE GUIDELINES?

Guidelines are systematically developed statements designed to assist the clinician and patient in making decisions about appropriate healthcare for certain specific clinical circumstances.⁴

In radiology, guidelines assist the process of selecting the appropriate imaging pathway. Such guidelines, called ‘selection criteria’, or ‘referral criteria’, exist for both medical and dental imaging. Radiographic referral criteria have been defined as:

“Descriptions of clinical conditions derived from patient signs, symptoms and history that identify patients who are likely to benefit from a particular radiographic technique.”⁵

Every dental practice using x-rays for diagnosis must have radiographic referral guidelines.³ As with any guideline, selection criteria are not intended to be rigid constraints on clinical practice, but “a concept of good practice against which the needs of the individual patient can be considered”.⁶ The term ‘referral criteria’ is appropriate for medical practitioners, where radiography is usually arranged by referral to a specialist in radiology. In primary dental care, referral to another clinician is not normal, so the term ‘selection criteria’ is widely used. In some cases, however, a practitioner may refer a patient to a colleague or to a hospital x-ray department for imaging, eg. for panoramic radiography or cone beam computed

tomography (CBCT). When referring patients in this way, they should ensure that adequate clinical information about the patient is provided to the person taking responsibility for the exposure. A request to, for example, “please take a panoramic radiograph for diagnosis” would not be considered adequate clinical information.

1.5 WHY EVIDENCE-BASED GUIDELINES?

There is increasing acceptance in medicine⁷ and dentistry⁸ that diagnostic and laboratory tests, clinical decisions and clinical practice should all be as ‘evidence-based’ as possible. This stance is supported by the UK Health Departments⁸ and the Royal Colleges^{10R} following lessons learned from clinical treatments that have subsequently been found to be ineffective and costly.

The evidence-based approach is not without problems, including the lack of high-quality research evidence in a number of clinical fields. The FGDP(UK) guidelines programme follows the SIGN (Scottish Intercollegiate Guidelines Network) approach to methodology¹¹ wherever possible, and adapts this, in a pragmatic way, to the particular area under review.

The scientific methodology of systematic reviews has developed dramatically in the last two decades and there are now established and rigorous methods that seek to ensure that the inherent (and often unintended) biases associated with many traditional reviews and professional panels are controlled effectively. SIGN was established in 1993 by the Academy of Medical Royal Colleges and their faculties in Scotland to support the development of national guidelines on a multi-professional basis. It is now seen as an international leader in this methodology. The key element of such guidelines is explicitly to link recommendations with levels of evidence and best practice for the delivery of patient-centred care.

In preparing this edition, due attention was paid to two highly relevant European guideline documents,^{5R,12R} both produced using rigorous systematic review and SIGN methodology. The first^{5R} deals with dental radiography in general, while the second^{12R} addresses the specific challenges of dental CBCT.

1.6 IMPLEMENTATION AND AUDIT

In order to influence practice positively and be of use in primary care, guidelines must be turned into useful aids for the provision of clinical care. This can best be done locally at a practice or clinic level.

Using the SIGN methodology and framework, a 'national guideline' is a series of broad statements that relate to the optimal level of care. 'Local guidelines' (protocols) are more detailed developments of these evidence-based broad principles for local application in individual practices.

In order to establish whether the national and local guidelines have had any effect, it is imperative that individual practitioners audit appropriate topics related to their implementation. Suggestions for possible audit topics are set out in Section 9.

1.7 REVIEW OF GUIDELINES

The first edition of *Selection Criteria for Dental Radiography*, published in 1998, set out to achieve much at a time when dental services and practices were evolving and when new research evidence was constantly being produced. A second edition, published in 2004, presented an update incorporating new evidence and developments, including the more widespread use of digital radiography. Since then, there have been a number of developments and some enhancement of the level of evidence to support recommendations. The developments include far greater use of digital radiography in dental practice. A 2010 paper¹³ suggested that in West Kent, 50% of general dentists used digital radiography. CBCT has also emerged and its use may well become more common over the next few years.

This third edition continues the process of review and evolution of the guidelines, taking such developments into consideration. In spite of the publication of a number of research projects on dental radiography, however, the level of evidence for the choice of particular types of radiographs in the oral cavity is sometimes still supported by clinical opinions rather than hard science. Throughout this book, where there is little evidence to support one type of radiography over another, this will be highlighted.

1.8 UNDERSTANDING THE GUIDELINES

As was the case with previous editions, it should be clearly understood that the approach adopted for different sections within this publication has not been uniform. This is because the volume of evidence available for review varies, as does the priority of the topics in terms of balancing risk and benefit. Some sections include more comprehensive sifting of the evidence, while others rely more heavily on expert opinion and conventional literature review.

The levels of evidence supporting each recommendation within this publication are indicated throughout, as shown in Table 1.1. This approach is consistent with the SIGN system of classification.¹¹

1.9 GUIDELINE METHODOLOGY

In order to provide guidelines in an evidence-based manner, much time and effort is expended. The dental literature was searched and appraised in a systematic fashion

Table 1.1: Levels of evidence supporting recommendations

GRADE

A

Requires at least one randomised controlled trial as part of the body of literature, of overall good quality and consistency, addressing the specific recommendations

GRADE

B

Requires availability of well-conducted clinical studies but no randomised clinical trials on the topic of recommendation

GRADE

C

Requires evidence obtained from expert committee reports or opinions and/or clinical experiences of respected authorities. Indicates absence of directly applicable clinical studies of good quality

to produce most of the recommendations made in this publication. References are indicated within the text by superscript numbering, in some cases along with the letter 'R' to indicate that the publication in question is a review article. Where relevant literature could not be identified for review, the authors have attempted to provide recommendations based on 'best practice' or expert opinion, following consultation with specialty groups.

At the very least, review questions for each subject area were set (Table 1.2). Literature was identified in a systematic manner by accessing electronic databases (MEDLINE, Embase, Index to Scientific & Technical Proceedings, Science Citation Index, and Social Sciences Citation Index). The publications deemed to be relevant to the carefully set review questions were critically appraised and recommendations were made from the strongest ones.

Table 1.2: Review questions

Review question	For all new, recall or emergency patients attending primary dental care:
1	When are radiographs indicated in order that a useful diagnostic yield will be generated (in comparison to the conventional clinical examination, with or without assistance from other methods) and thus contribute usefully to individual patient care plans for maintaining and improving dental health?
2	What significant additional age-related risk will follow from exposure to different dental radiographic projections?
3	What evidence exists to influence or support selection criteria by specialty area, in order to contribute usefully to individual patient care plans for maintaining and improving dental health?

1.10 GAPS IN THE EVIDENCE

The previous edition in 2004 identified gaps in the evidence where research was needed. Many of these remain unanswered and, with the availability of CBCT, new evidence needs have arisen. The following are suggestions for future research:

- The value of radiographs in periodontology
- Prevalence of hidden dentine caries (especially in low-prevalence groups)
- Caries-related data of individuals in their early twenties (and older)
- Crown and bridgework radiographs
- Practical caries risk assessment in primary care
- The need for a pre-extraction radiograph
- Economic evaluations (cost-benefit analysis) of dental imaging
- Application of alternatives to radiography for caries detection
- Clinical trials of patient clinical outcomes when using CBCT compared with conventional radiographs
- Research on image quality requirements of CBCT for different clinical applications

1.11 OVERVIEW OF RECOMMENDATIONS

An overview of the recommendations appears as Appendix 1.

1.12 REFERENCES

1. National Radiological Protection Board (NRPB). Guidelines on Radiology Standards for Primary Dental Care: Report by the Royal College of Radiologists and NRPB. Documents of the NRPB: 5(3). Chilton: NRPB; 1994.
2. International Atomic Energy Agency. Justification of medical exposure in diagnostic imaging. Vienna: IAEA, 2011. Available at: www-pub.iaea.org/MTCD/Publications/PDF/Pub1532_web.pdf. Accessed: August 2012.
3. The Ionising Radiation (Medical Exposure) Regulations 2017. London, Department of Health: 2017.
4. Field MJ, Lohr KN. Guidelines for clinical practice: from development to use. Washington DC: National Academic Press; 1992.
5. [R] European Commission. Radiation Protection 136: European Guidelines on Radiation Protection in Dental Radiology. Luxembourg: Publications Office of the European Union; 2004. Available at: http://ec.europa.eu/energy/nuclear/radioprotection/publication/doc/136_en.pdf. Accessed: August 2012.
6. Royal College of Radiologists. Medical audit in radiodiagnosis. London: RCR; 1990.
7. Sackett DL, Rosenberg WMC, Gray JAM, Haynes RB, Richardson WS. Evidence-based medicine: what it is and what it isn't. *BMJ* 1996;312:71–2.
8. Richards D, Lawrence A. Evidence-based dentistry. *Br Dent J* 1995;179:270–3.
9. Department of Health. Research and development: towards an evidence-based health service. London: DH; 1995.
10. [R] Sackett DL, Rosenberg WMC. The need for evidence-based medicine. *J R Soc Med* 1995;88:620–4.
11. Scottish Intercollegiate Guidelines Network. SIGN 50: A guideline developers' handbook, revised ed. Edinburgh: SIGN; 2008.
12. [R] European Commission. Radiation Protection 172. Cone beam CT for dental and maxillofacial radiology: evidence based guidelines. Luxembourg: European Commission; 2012. Available at: <https://ec.europa.eu/energy/sites/ener/files/documents/172.pdf> . Accessed: January 2018
13. Mauthe P, Eaton KA. An investigation into dental digital radiography in dental practices in west Kent following the introduction of the 2006 NHS General Dental Services contract. *Prim Dent Care* 2011;18:73–82.

Note: [R] indicates a review publication.

2

USE OF IONISING RADIATION

2.1 RADIATION DOSES AND RISKS IN DENTAL PRACTICE

Nicholas Drage and Anne Walker

2.1.1 Introduction

Radiography is an invaluable tool for the clinician, providing information that is impossible to obtain by clinical examination alone. Of all the x-ray examinations carried out in the UK, around 26% are taken by general dental practitioners.¹ In 2008, it was estimated that 20.5 million dental radiographs were taken by dentists in NHS and private practice, and of these 2.7 million were panoramic radiographs.¹ Consequently dentists, equipment manufacturers, medical physics experts and radiation protection advisers need to work to keep radiation doses and risks as low as reasonably practicable. If selection criteria are used properly, the collective dose to the population is reduced, since unnecessary or unproductive x-ray examinations are eliminated.

X-rays are a type of electromagnetic (EM) radiation. EM radiation also includes visible light, radiowaves, microwaves, cosmic radiation and several other varieties of 'rays'. All can be considered as 'packets' of energy, called photons, which have wave properties, most importantly a wavelength and frequency. X-rays are short-wavelength, high-frequency EM radiation. The importance of this is that high frequency means high energy. When x-rays hit atoms this energy can be transferred, causing ionisation of the atoms.

2.1.2 Radiation damage

An x-ray beam consists of millions of high-energy photons. These can damage molecules by ionisation of atoms, but damage to the DNA in the chromosomes

is of particular importance. Most DNA damage is successfully repaired, but rarely a portion of a chromosome may be permanently altered (a mutation). This may lead to uncontrolled cell replication, ultimately leading to the formation of a tumour. The latent period between exposure to x-rays and diagnosis of a tumour may be many years. The probability of a tumour being produced is related to the radiation dose, so knowledge of the doses delivered is important. Such effects where the magnitude of the risk is related to dose can be considered as 'chance' (stochastic) effects. For these effects there is no clear evidence of the existence of a safe level of radiation dose,^{2,3} ie. it is currently assumed that any level of dose could lead to tumour induction. However, the lower the radiation dose, the lower the risk of radiation-induced tumours.

There is strong, well documented epidemiological evidence that exposure to radiation at doses above some tens of millisieverts is associated with an increased risk of cancer.⁴ Studies have shown increased cancer risk associated with CT scans in childhood and raised levels of exposure to background radiation.^{5,6} Dose levels associated with dental radiology are even smaller; however, a number of epidemiological studies have provided evidence of a possible increased risk of brain, salivary gland and thyroid tumours related to dental radiography.⁷⁻¹⁶

Another stochastic effect is that of heritable damage seen in the children of irradiated parents. As the radiation dose to the reproductive organs is so low in dental examinations, the risk of heritable effects is negligible.^{17R}

There are other known damaging effects of radiation, such as skin erythema, hair loss and effects on fertility, that definitely have threshold doses below which they will not occur. As dental radiography would never exceed these thresholds which are some thousands of millisieverts, except in extraordinary circumstances, these tissue reactions or deterministic effects are given no further consideration. Cataract formation was, until recently, believed to have a similar threshold; however, the evidence has indicated a threshold of about 500 mSv, a factor of three lower than previously thought.^{2,18} This level is still well above that observed in dental radiography, but risk of cataract induction could become a concern if many repeated CBCT or CT examinations which included the orbits were undertaken.

2.1.3 Radiation dose

The term 'dose' is widely used but often misunderstood. There are three common terms used to describe dose: absorbed dose, equivalent dose and effective dose.

ABSORBED DOSE (D)

Of the three dose quantities, this is the only one that can be directly measured. The absorbed dose is the mean energy imparted to a unit mass of matter (eg. tissue) by the ionising radiation.² The units of measurement are joules per kilogram (J/kg), which are called grays (Gy).

EQUIVALENT DOSE (H_T)

Some types of ionising radiation are more damaging to tissue than others. This is taken into account when making dose calculations by weighting the absorbed dose depending on the type of radiation used. For instance, alpha particles will potentially cause much more biological damage than x-rays for the same absorbed dose, and so they are given a weighting 20 times that of x-ray photons. For dental radiography, which only uses x-rays, the absorbed dose and the equivalent dose are numerically the same. Equivalent dose is still measured in J/kg, but its unit is given the special name of sievert (Sv).

EFFECTIVE DOSE (E)

Different tissues of the body are more susceptible to the effects of ionising radiation than others. This is taken into account when calculating the effective dose. The International Commission on Radiological Protection (ICRP) has published revised tissue weighting factors for the most radiosensitive tissues of the body.² The modifications were introduced mainly on the basis of new epidemiological evidence of cancer induction in the survivors of the Japanese atomic bombs. The main changes relevant to the calculation of effective dose from dental radiography are the addition of the salivary glands as an individual weighted tissue and the inclusion of the oral mucosa in the remainder tissues. Consequently, effective doses calculated using the current ICRP recommendations for dental exposures are significantly higher than using the previous weighting factors.^{19–21} Therefore, caution must be taken when trying to compare effective doses calculated using different weighting factors.

In dentistry, the effective dose is often small, so it is more appropriate to use subunits such as the millisievert (mSv) which is one thousandth of a Sv, or the microsievert (μ Sv), which is one millionth of a Sv.

2.1.4 Factors influencing effective dose

The radiation dose delivered for a specific imaging requirement can be determined by a range of factors, some related to the equipment type and design, others to the operator's use of the equipment. They can be grouped into three categories:

- The sensitivity of the image receptor – using a high-speed (i.e. more sensitive) system will reduce the dose required.
- The area exposed to the primary beam – reducing the volume exposed and ensuring that more sensitive organs are in areas of lower dose will limit the effective dose.
- The exposure factors selected – selecting equipment settings that give lower dose while maintaining adequate image quality.

Correct selection of equipment and technique can significantly reduce the patient dose. However, dose should not be reduced to such a level that the image quality is not adequate for the clinical purpose. There is a balance between radiation dose and image quality, and the operator must be trained to understand how the factors interact to optimise the imaging process.

INTRAORAL RADIOGRAPHY

It is recommended that intraoral dental x-ray equipment should have the following design features:²²

- Equipment should operate at a voltage between 60–70kV.
- Constant potential units are preferred to generators with pulsating waveforms.
- The beam must be adequately filtered using an appropriate thickness of aluminium.
- An open-ended spacer cone should be used in conjunction with rectangular collimation.
- A long focus-to-skin distance should be used (200mm for sets operating between 60–70 kV).

- A range of available exposure times of sufficiently fine graduations to produce optimally exposed radiographs over the full range of possible patient sizes, anatomical views and speeds of imaging system.

In addition, a sensitive image detector system should be used, such as F-speed film or a digital detector. The use of modern equipment combined with good technique and sensitive detectors can make a tenfold difference to the effective dose.¹⁹ A national review of dose in dental practice in the UK found that the average dose for an adult molar setting had decreased by 57% since 1999 as a result of the adoption of new equipment and more sensitive image detectors.²³

A number of studies have compared doses in digital and film intraoral radiography in which the dose reduction offered by digital over conventional film ranged between 20–70%.^{24,25} However, Berkhout *et al*²⁴ put forward the caveat that in practice it is likely that the overall dose reduction is less than 25%, owing to the tendency to take more images when using digital systems. In addition, owing to the greater range of dose that will give acceptable images, care must be taken to use the level of dose that will give an *acceptable* image as opposed to the best image, which is likely to be at a significantly higher dose.²⁶

PANORAMIC AND CEPHALOMETRIC RADIOGRAPHY

There are also marked differences in the doses associated with different panoramic machines, primarily related to the speed of the detector and the selection of beam sizes available.²⁷ Modern film screen systems have speeds very similar to current digital detectors, and it is unlikely that the introduction of digital technology will see the same dose reduction in either panoramic or cephalometric radiography as is currently being experienced in intraoral radiography.²⁷

CONE BEAM COMPUTED TOMOGRAPHY

CBCT is the most significant development in dental and maxillofacial imaging in recent years. The first commercially available machine on the market was introduced in the late 1990s, and there are now a large number of manufacturers producing CBCT machines. High-resolution, three-dimensional images of teeth and jaws are produced.

Consequently, there are several applications of CBCT in dentistry including endodontics, orthodontic diagnosis and the assessment of the jaw prior to implant placement.^{28–30} The European Commission has produced evidence-based referral criteria to clarify those clinical situations in which CBCT may be useful.^{31R} CBCT units are significantly cheaper than medical CT machines and have a much smaller footprint. These features, combined with the potential for increased diagnostic yield, make these systems attractive to dentists working outside the hospital sector.

The effective dose from CBCT is dependent on many factors, with one of the main ones being the volume of tissue irradiated. The volume of tissue that is irradiated is often referred to as the field of view (FoV). Comparison of effective dose with respect to FoV size is shown in Table 2.1. There is a marked range in the effective doses in each category because of differences in the equipment being used, including the detector type and the scanning parameters selected (tube current, voltage and time of exposure, including the number of projections obtained).

In addition, for small FoV scanners the dose varies depending on the region of the jaw being scanned.⁴⁷ Some machines allow a choice of exposure factors and offer a wide choice of FoVs, while on other units these features are either fixed or there is a limited choice. These factors must be one of the prime considerations when considering buying such a unit. It is important that the exposure factors and FoV are optimised to the clinical question being investigated.^{31R,60} There is no need for the routine use of lead aprons for patients undergoing CBCT examinations.^{31R,60} However, there is some evidence to support the use of a thyroid shield for CBCT, as this may reduce the effective dose by up to 40%.^{58,61} If a thyroid shield is used, it must be positioned carefully so as not to cause artefacts on the images or obscure areas of interest.⁶⁰

The effective dose from medical CT is generally higher than that from CBCT. However, scanning parameters can be optimised to reduce the dose considerably,^{50,62–64} with the advantage that soft-tissue differentiation is still possible even with low exposure factors.

Table 2.1: Effective doses for traditional dental radiography, CBCT and CT examinations – tabular summary of literature review

Radiographic technique	Effective dose (μSv)	References
Intraoral radiograph (bitewing/periapical)	0.3–21.6	19,32,33
Panoramic radiograph	2.7–38	19,21,32–42
Lateral cephalometric radiograph	2.2–14	19,36,42–46
CBCT (small field of view*)	11–214	35,47–53
CBCT (medium field of view**)	18–674	20,35,37,42,47–55
CBCT (large field of view***)	60–510.6	20,21,35,41,51,52,54–56
CBCT (extended field of view****)	30–1025	20,21,41,42,46,47,54–58
CT scan (mandible)	250–1410	34,36,47,50
CT Scan (mandible and maxilla)	430–860	35,54,59

* The height of cylindrical volume or spherical diameter of the volume $\leq 5\text{cm}$

** The height of cylindrical volume or spherical diameter of the volume $> 5\text{cm}$ and $\leq 10\text{cm}$.

*** The height of cylindrical volume or spherical diameter of the volume $> 10\text{cm}$ and $\leq 15\text{cm}$

**** The height of cylindrical volume or spherical diameter of the volume $> 15\text{cm}$

2.1.5 The risks

It is useful to understand the magnitude of the risk associated with dental radiography when considering the justification of individual dental exposures and the effect of dental exposures on the whole population. Risk factors are regularly published and are constantly being refined as new data becomes available and more sophisticated modelling is undertaken.^{2,65}

As discussed in Section 2.1.2, above, the risk associated with dental radiography is primarily that of cancer induction. A publication by the UK Health Protection Agency proposes the use of a total lifetime cancer induction risk factor for an average 30-to-39-year-old of 6.8% per Sv for men and 5.5% per Sv for women for radiography of the head.⁶⁵ Another way of expressing this is to say that there is a 1 in 15,000 (for men)

and 1 in 18,000 (for women) risk of a cancer being induced for every 1mSv effective dose received from dental radiography.

Risk is age-dependent, being highest for the young and lowest for the elderly. The tissues of younger people are more radiosensitive and their prospective life span is likely to exceed the latent period. For the very elderly, life expectancy will be less than the latency period, which can be anything from five years upwards and the risk could be considered negligible. In general, young children are at about two to three times the risk of develop radiation-induced cancer than adults in their thirties for the same effective dose,⁶⁵ hence the importance of using specific paediatric exposure protocols when radiographing children to ensure that the dose is minimised.

There is often considerable concern about radiography during pregnancy because of possible risk to the foetus. In dental radiography, it is unusual for an x-ray beam to be pointed at the abdomen (only for vertex occlusal radiographs, which are rarely indicated) and, in those cases where radiography is essential, abdominal lead protection should be used when a foetus lies in the primary beam.²² For all other dental radiographic views, including panoramic and CBCT examinations, there is no requirement to delay radiography until after the birth. However, as the subject of radiography during pregnancy is emotive, it is recommended that practitioners offer pregnant patients the option of delaying non-urgent radiography.^{66,67}

Table 2.1 gives typical doses for radiographic examinations of teeth and jaws, including dental radiographic techniques likely to be used in primary dental care. The doses have been calculated either using the current ICRP recommendations or, in those studies that predate these recommendations, those ones that include weighting factors for the salivary glands. Effective doses are calculated for a reference patient and there are many uncertainties in the calculations. Risk estimates for an individual based on the calculated effective dose may be higher or lower by a factor of five.⁶⁸ For this reason, risk has been split into broad categories to indicate the health detriment.⁶⁸ The risk from dental radiography falls into the lowest risk category. Even the risk from medical CT of the jaws is considered very low. However low the risk from the examination, it is

imperative that each radiographic exposure is fully justified and the doses optimised to reduce the detrimental effects to the lowest possible level.

2.1.6 Diagnostic reference levels

Surveys of dental radiography practice have consistently shown a significant variation in dose for the same examinations between dental practices. In the 2005 survey of dental practices, the dose for the same intraoral dental radiographic examination varied by a factor of 600 between the lowest and highest doses.²⁷

The concept of diagnostic reference levels (DRLs) has been developed in response to such wide variations in patient doses to provide an audit standard. National reference levels for conventional dental radiography are based on the third-quartile values for the distribution of doses found in such surveys, ie. 75% of equipment gives doses below the reference value.^{69,70} Auditing patient dose and comparison with locally-set DRLs is a legal requirement in the UK.^{71,72} Those dentists with equipment giving doses above the local DRL need to investigate the cause and instigate measures to reduce the doses to below the local DRL. For general dental practice it is recommended that these national reference levels are adopted as the local DRLs, ie. local audit standards,²² unless local measurements of patient doses support the adoption of lower values. This should be determined with the help of your medical physics expert. The current recommended national reference levels for dental radiography are shown in Table 2.2 (overleaf).

Audit data are not yet available for the establishment of a national DRL for CBCT. However, local DRLs should be set up with the help of a medical physics expert.⁷⁴ The Health Protection Agency (now part of Public Health England) carried out an initial analysis and recommended an achievable dose based on the ability to collimate to the area of clinical interest.⁷⁴

There have been some encouraging signs from the 2005 and 2010 surveys.^{23,27} In comparison to the 1999 survey, there has been an overall reduction of dose arising from intraoral radiography, mainly due to the higher voltage of the x-ray machines used, the use of faster film and the increased use of digital radiography.

Table 2.2: Suggested national diagnostic reference levels for dental radiography

Examination	National Diagnostic Reference Level	References
Intraoral (adult molar)	1.7 mGy*	23
Panoramic (adult)	93 mGy cm ² **	23
Panoramic (child)	67 mGy cm ² **	23
Lateral cephalometric radiograph (adult)	40 mGy cm ²	73
Lateral cephalometric radiograph (child)	25 mGy cm ²	73
	Achievable Dose	
CBCT (adult upper first molar implant)	250 mGy cm ² **	73

* measured as the absorbed dose in air at the end of the spacer cone

** measured as the dose area product (DAP)

2.1.7 Doses and risks in context

Life is a risky business. We are all constantly exposed to naturally occurring background radiation, which averages about 2230 μSv each year in the UK.⁷⁵ Medical exposures (including dental) add around 18% to this figure on average (per UK citizen) and this proportion continues to rise, primarily due to the increased use of CT scanners.⁷⁵ With this in mind a periapical radiograph may be associated with an effective dose up to three and a half days' background radiation and a panoramic radiograph equivalent to no more than six days' background radiation. The effective dose from a CBCT examination is comparable to between two days' and six months' additional background radiation, depending on the machine used and the exposure parameters selected. For comparative purposes, a chest x-ray (18 μSv) is equivalent to around three days of additional background radiation, while some medical computed tomography examinations equate to over ten years' background radiation.^{76–78}

Unfortunately, one in four people in the UK die from cancer.⁷⁹ Radiography increases the chance of developing cancer, and it is estimated that diagnostic radiology (medical and dental) causes 700 cancer cases per year in the UK.⁸⁰ The collective dose to the population from dental radiography is low so only a small proportion of these cancers can be attributed to dental radiography.⁸¹ However, choosing to radiograph a patient and selecting the technique and its frequency should be a matter of balancing the risk against the clinical benefits to that patient.

A

No patient should be expected to receive additional radiation dose and risk as part of a course of dental treatment unless they are likely to benefit from dental radiography.

Notwithstanding the already low individual risk, every effort should be made to undertake the radiography at minimum dose to the patient. The lowest-dose examination that will answer the clinical question should always be undertaken.*

*This important statement is given the highest level of recommendation even though there are no randomised controlled trials to support it. Such a study design would be neither possible nor ethical.

2.2 THE USE OF PANORAMIC RADIOGRAPHY

Vivian Rushton

Panoramic radiography has become a well-established radiographic technique in general dental practice. One study has found that 63% of general dental practitioners routinely screened their new adult patients using panoramic radiography.⁸² This increase in panoramic screening is not surprising, since as long ago as 2003, 61% of general dental practitioners had access to this type of radiographic equipment.⁸³

As with all radiographic examinations, it is important to strike a balance between the radiation dose received by the patient and the likely diagnostic benefit. As detailed in

Table 2.1, panoramic equipment delivers a wide range of dose to patients depending on the type of equipment used, with newer panoramic units more likely to incorporate dose-limiting features. Irrespective of these developments, within the last ten years radiation dose reduction from panoramic radiography has been low (<10%),²⁷ in part because some digital panoramic systems may require an increase in exposure factors compared with fast screen/film combinations.⁷⁰

There is continuing evidence of poor image quality of panoramic radiographs taken in primary dental care.^{84,85} Any faults in the radiograph will inevitably lead to a reduction in the diagnostic value of the examination. It is essential that particular care should be taken in monitoring and maintaining high image quality by paying close attention to correct positioning of the patient and, for film-based radiography, by ensuring the best possible processing techniques. The dental practice should also employ a robust quality assurance programme. The latter is a statutory requirement of the Ionising Radiations Regulations 2017.⁷¹



Routine monitoring of panoramic image quality is essential in order to maximise diagnostic value.*

*While there is insufficient research to support a higher grading for this statement, it is a requirement of current legislation.⁷¹

2.2.1 *The new patient to the practice*

In some centres, it has become routine to take a panoramic radiograph of all new patients. Research has shown that intraoral (bitewing and periapical) radiographs are superior to panoramic radiographs for the diagnosis of common dental pathosis (caries, periodontal and periapical pathology).^{86R,87-89} However, a high proportion of dentists rely on panoramic radiography alone to assess common dental pathosis.⁹⁰

Some dentists use panoramic radiography routinely to ‘screen’ the jaws for clinically unsuspected pathology.⁹⁰ It is possible that anecdotal evidence of identifying a cyst or other unusual lesion in a patient may reinforce this attitude. This standpoint,

however, ignores the low prevalence of asymptomatic pathology. Routine radiography without the presence of clinical signs or symptoms cannot be justified.^{86R, 91} This has long been recognised in medical radiological practice, resulting in the cessation of screening practices, except for those national screening programmes with a strong evidence base, such as the Breast Screening Programme.

It can be argued that a panoramic radiograph may be appropriate for the patient who presents with a grossly neglected mouth with significant numbers of clinically determined caries lesions and periapical pathosis, along with established periodontal disease (other than simple gingivitis).^{92,93} In these cases, it may be expeditious to use panoramic radiography as a means of identifying teeth requiring a more detailed (intraoral) radiographic examination or, when limited to a hospital setting, prior to dental surgery under general anaesthesia.

2.2.2 The edentulous patient

In the absence of any clinical signs or symptoms, there is no justification for any radiographic examination,⁹⁴ unless implant treatment is planned (see Section 8). Where clinical examination identifies the possible presence of an abnormality, such as a possible retained root, then an intraoral radiograph of the site is the appropriate radiographic examination.

2.2.3 The orthodontic patient

A panoramic radiograph is commonly used to provide information on the state of the developing dentition and is often appropriate when orthodontic treatment is being considered. This is considered fully in Section 3.

Several studies have examined the efficacy of radiography, including panoramic, in orthodontic practice.^{95–100} The researchers reported the limited effect radiography has on changing orthodontic diagnosis or treatment plans. Although radiography has an undoubted role in orthodontic practice, such research questions whether the present use of radiography may be excessive. Routine screening of children cannot be justified and the use of selection criteria¹⁰⁰ has been found to be effective in determining those children likely to benefit from a radiographic examination.

Guidance from the British Orthodontic Society reflects this approach.¹⁰¹

2.2.4 *Prior to oral surgery*

Routine radiography of unerupted third molars is not recommended.¹⁰² The panoramic radiograph is commonly used to assess third molars prior to their surgical removal but does not need to be carried out at the initial examination.¹⁰² In the case of mandibular third molars, the radiograph will provide information about the distance to the lower border of the mandible and the limited information about the course and relationship with the inferior dental canal. With the latter, it should be noted that panoramic radiography does not provide an accurate indication of a close relationship.^{103–105} In those surgical cases in which there is a suggestion of a close relationship between the root apices and the mandibular canal, either a second radiograph, using different projection geometry,¹⁰⁵ or, if available, a localised CBCT examination^{31R} should be performed if this is likely to result in a change in surgical management. There is a risk of localised CBCT examinations becoming standard “defensive” practice. It is emphasised that there is no evidence to support the use of CBCT routinely in these cases, nor any evidence of any improvement in patient outcomes when CBCT is used in such situations.

In other surgical situations, such as apicectomy, root removal or enucleation of small cysts, an intraoral radiograph may be all that is required for treatment planning and the use of panoramic radiography would not normally be needed.

2.2.5 *Trauma*

For simple dental trauma, intraoral radiography will provide the greatest diagnostic detail. A panoramic radiograph is, however, the first-choice method for imaging mandibular fractures,^{106,107} although poor panoramic image quality has been shown to limit diagnostic accuracy.¹⁰⁸ Supplementary imaging is often required to diagnose high condylar fractures.^{107,109,110} Panoramic radiography has a limited ability to detect mid-facial fractures. If there is clinical evidence of a bone fracture, it is probably more appropriate to refer the patient for a complete radiographic examination at the hospital, where treatment will be performed.

2.2.6 Temporomandibular joint problems

The panoramic radiograph shows an image of the mandibular condyles and is often used as a first-choice imaging technique for those patients with TMJ symptoms. A study of patients with TMJ symptoms has found, however, that panoramic radiography provided little or no information that influenced diagnosis or patient management in most cases examined.¹¹¹

The overwhelming majority of patients with symptoms and signs related to the TMJ region are suffering from myofascial pain/dysfunction or internal disc derangements. Condylar abnormality is not seen in the former and only occasionally in the latter. Radiography is not recommended for patients with joint sounds ('clicking') in the absence of other signs or symptoms.^{112,113} Radiographic examination is indicated where there is recent evidence of progressive pathology (recent trauma, change in occlusion, mandibular shift, sensory or motor alterations, change in range of movement).

2.2.7 Conclusions

Panoramic radiological examinations are performed on large numbers of patients either as an alternative, or as a supplement, to intraoral radiography. The criteria used in the decision to take a panoramic radiograph may be specific clinical indicators or an indiscriminate 'screening' procedure for pathology. The many published studies on the diagnostic accuracy, sensitivity and specificity of panoramic radiology compared to intraoral radiographic examinations indicate that it is generally inferior in the imaging of the dental diseases with the greatest prevalence.

A

All patients must have a history taken and clinical examination performed prior to panoramic radiography. Where radiographs are clinically indicated in dental practice, intraoral radiography should be considered the optimal radiographic examination because of better detail and lower radiation doses.

Panoramic radiography should not be seen as a routine radiographic technique for general dental practice, but rather one selected for specific situations on the basis of clinical history and examination. Table 2.3 suggests some selection criteria.

Table 2.3: Suggested selection criteria for panoramic radiography and the level of evidence supporting the recommendation.

Criterion	Evidence grade
Where a bony lesion or unerupted tooth is of a size or position that precludes its complete demonstration on intraoral radiographs.	C
In patients with a grossly neglected dentition, for whom there is a clinically determined likelihood of multiple extractions being required.	C
For the assessment of third molars prior to planned surgical intervention. Routine radiography of unerupted third molars is not recommended.	B
As part of an orthodontic assessment where there is a clinical need to know the state of the dentition and the presence/absence of teeth. The use of clinical criteria to select patients rather than routine screening is essential (see Section 3).	C
Panoramic radiographs should only be taken in the presence of specific clinical signs and symptoms. There is no justification for review panoramic radiography at arbitrary time intervals.	B

2.3 REFERENCES

1. Hart D, Wall BF, Miller MC, Shrimpton PC. HPA–CRCE–012. Frequency and collective dose for medical and dental x-ray examinations in the UK, 2008. Chilton: HPA; 2010.
2. The 2007 recommendations of the International Commission on Radiological Protection. ICRP Publication 103. Ann ICRP 2007;37:1–332.
3. European Commission. Radiation Protection 125: Low dose ionizing radiation and cancer risk. Luxembourg: Office for Official Publications of the European Communities; 2001.
4. Mobbs SF, Muirhead CR, Harrison JD. Risks from ionising radiation. HPA–RPD–066. Chilton: HPA; 2010. Available from: <https://ec.europa.eu/energy/sites/ener/files/documents/125.pdf> (Accessed January 2018).
5. Pearce MS, Salotti JA, Little MP, McHugh K, Lee C, Kim KP et al. Exposure from CT scans in childhood and subsequent risk of leukaemia and brain tumours: a retrospective cohort study. *Lancet* 2012;380:499–505.
6. Kendall GM, Little MP, Wakeford R, Bunch KJ, Miles JCH, Vincent TJ et al. A record based case-control study of natural background radiation and the incidence of childhood leukaemia and other cancers in Great Britain during 1980–2006. *Leukemia* 2013;27:3–9.
7. Preston-Martin S, White SC. Brain and salivary gland tumors related to prior dental radiography: implications for current practice. *J Am Dent Assoc* 1990;120:151–158.
8. Longstreth WT, Dennis LK, McGuire VM, Drangsholt MT, Koepsell TD. Epidemiology of intracranial meningioma. *Cancer* 1993;72:639–648.
9. Longstreth WT Jr, Phillips LE, Drangsholt M, Koepsell TD, Custer BS, Gehrels JA et al. Dental x-rays and the risk of intracranial meningioma: a population-based case-control study. *Cancer* 2004;100:1026–34.
10. Ryan P, Lee MW, North B, McMichael AJ. Amalgam fillings, diagnostic dental x-rays and tumours of the brain and meninges. *Eur J Cancer B Oral Oncol* 1992;28B:91–5.
11. Claus EB, Calvocoressi L, Bondy ML, Schildkraut JM, Wiemels JL, Wrensch M. Dental x-rays and risk of meningioma. *Cancer* 2012;118:4530–7.
12. Preston-Martin S, Thomas DC, White SC, Cohen D. Prior exposure to medical and dental x-rays related to tumors of the parotid gland. *J Natl Cancer Inst* 1988;80:943–949.
13. Horn-Ross PL, Ljung BM, Morrow M. Environmental factors and the risk of salivary gland cancer. *Epidemiology* 1997;8:414–419.
14. Hallquist A, Hardell L, Degerman A, Wingren G, Boquist L. Medical diagnostic and therapeutic ionizing radiation and the risk for thyroid cancer: a case-control study. *Eur J Cancer Prev* 1994;3:259–267.
15. Wingren G, Hallquist A, Hardell L. Diagnostic x-ray exposure and female papillary thyroid cancer: a pooled analysis of two Swedish studies. *Eur J Cancer Prev* 1997;6:550–556.
16. Memon A, Godward S, Williams D, Siddique I, Al-Saleh K. Dental x-rays and the risk of thyroid cancer: a case control study. *Acta Oncologica* 2010;49:447–453.
17. [R] White SC. 1992 Assessment of radiation risk from dental radiography. *Dentomaxillofac Radiol* 1992;21:118–126.
18. International Commission on Radiological Protection. 2011 Statement on tissue reactions. Available at <http://www.icrp.org/page.asp?id=123> Accessed: March, 2013.
19. Ludlow JB, Davies-Ludlow LE, White SC. Patient risk related to common dental radiographic examinations: the impact of 2007 International Commission on Radiological Protection recommendations regarding dose calculation. *J Am Dent Assoc* 2008;139:1237–43.
20. Roberts JA, Drage NA, Davies J, Thomas DW. Effective dose from cone beam CT examinations in

dentistry. *Br J Radiol* 2009;82:35–40.

21. Ludlow JB, Davies-Ludlow LE, Brooks SL, Howerton WB. Dosimetry of three CBCT devices for oral and maxillofacial radiology: CB Mercuray, NewTom 3G and i-CAT. *Dentomaxillofac Radiol* 2006;35:219–26. Erratum in: *Dentomaxillofac Radiol*. 2006;35:392.
22. National Radiological Protection Board. Guidance notes for dental practitioners on the safe use of x-ray equipment. NRPB. London: Department of Health; 2001.
23. Hart D, Hillier MC and Shrimpton PC. Doses to patients from radiographic and fluoroscopic x-ray imaging procedures in the UK (2010 Review). HPA–CRCE–034. Chilton: HPA; 2012.
24. Berkhout WER, Sanderink GCH and Van der Stelt PF. Does digital radiography increase the number of intraoral radiographs? A questionnaire study of Dutch dental practices. *Dentomaxillofac Radiol* 2003;32:124–127.
25. Bhaskaran V, Qualtrough AJE, Rushton VE, Worthington HV, Horner K. A laboratory comparison of three imaging systems for image quality and radiation exposure characteristics. *Int Endod J* 2005;38:645–652.
26. Berkhout WER, Beuger DA, Sanderink GCH and Van der Stelt PF. The dynamic range of digital radiographic systems: dose reduction or risk of overexposure? *Dentomaxillofac Radiol* 2004;33:1–5.
27. Gulson AD, Knapp TA, Ramsden PG. Doses to patients arising from dental x-ray examinations in the UK, 2002–2004. A review of dental x-ray protection service data. HPA–RPD–022. Chilton: HPA; 2007.
28. Rigolone M, Pasqualini D, Bianchi L, Berutti E, Bianchi SD. Vestibular surgical access to the palatine root of the superior first molar: “low-dose cone-beam” CT analysis of the pathway and its anatomic variations. *J Endod* 2003;29:773–5.
29. Walker L, Enciso R, Mah J. Three-dimensional localization of maxillary canines with cone-beam computed tomography. *Am J Orthod Dentofacial Orthop* 2005;128:418–23.
30. Guerrero ME, Jacobs R, Loubele M, Schutyser F, Suetens P, van Steenberghe D. State-of-the-art on cone beam CT imaging for preoperative planning of implant placement. *Clin Oral Investig* 2006;10:1–7.
31. [R] SENDENTEXCT. Radiation Protection 172. Cone beam CT for dental and maxillofacial radiology: evidence based guidelines. Luxembourg: European Commission; 2012. Available at: http://ec.europa.eu/energy/nuclear/radiation_protection/doc/publication/172.pdf. Accessed: July, 2012.
32. Looe HK, Eenboom F, Chofor N, Pfaffenberger A, Steinhoff M, Rühmann A, Poplawski A, Willborn K, Poppe B. Conversion coefficients for the estimation of effective doses in intraoral and panoramic dental radiology from dose-area product values. *Radiat Prot Dosimetry* 2008;131:365–73.
33. Palomo JM, Rao PS, Hans MG. Influence of CBCT exposure conditions on radiation dose. *Oral Surg Oral Med Oral Pathol Oral Radiol Endod* 2008;105:773–82.
34. Ohman A, Kull L, Andersson J, Flygare L. Radiation doses in examination of lower third molars with computed tomography and conventional radiography. *Dentomaxillofac Radiol* 2008;37:445–52.
35. Okano T, Harata Y, Sugihara Y, Sakaino R, Tsuchida R, Iwai K, et al. Absorbed and effective doses from cone beam volumetric imaging for implant planning. *Dentomaxillofac Radiol* 2009;38:79–85.
36. Lecomber AR, Yoneyama Y, Lovelock DJ, Hosoi T, Adams AM. Comparison of patient dose from imaging protocols for dental implant planning using conventional radiography and computed tomography. *Dentomaxillofac Radiol* 2001;30:255–9.
37. Ludlow JB, Davies-Ludlow LE, Brooks SL. Dosimetry of two extraoral direct digital imaging devices: NewTom cone beam CT and Orthophos Plus DS panoramic unit. *Dentomaxillofac Radiol* 2003;32:229–34.

38. Lecomber AR, Downes SL, Mokhtari M, Faulkner K. Optimisation of patient doses in programmable dental panoramic radiography. *Dentomaxillofac Radiol* 2000;29:107–12.
39. Gijbels F, Jacobs R, Bogaerts R, Debaveye D, Verlinden S, Sanderink G. Dosimetry of digital panoramic imaging. Part I: Patient exposure. *Dentomaxillofac Radiol* 2005;34:145–9.
40. Gavala S, Donta C, Tsiklakis K, Boziari A, Kamenopoulou V, Stamatakis HC. Radiation dose reduction in direct digital panoramic radiography. *Eur J Radiol* 2009;71:42–8.
41. Silva MA, Wolf U, Heinicke F, Gründler K, Visser H, Hirsch E. Effective dosages for recording Veraviewepocs dental panoramic images: analog film, digital, and panoramic scout for CBCT. *Oral Surg Oral Med Oral Pathol Oral Radiol Endod* 2008;106:571–7.
42. Grünheid T, Kolbeck Schieck JR, Pliska BT, Ahmad M, Larson BE. Dosimetry of a cone-beam computed tomography machine compared with a digital x-ray machine in orthodontic imaging. *Am J Orthod Dentofacial Orthop* 2012;141:436–43.
43. Looe HK, Eenboom F, Chofor N, Pfaffenberger A, Sering M, Rühmann A, Poplawski A, Willborn K, Poppe B. Dose-area product measurements and determination of conversion coefficients for the estimation of effective dose in dental lateral cephalometric radiology. *Radiat Prot Dosimetry* 2007;124:181–6.
44. Gijbels F, Sanderink G, Wyatt J, Van Dam J, Nowak B, Jacobs R. Radiation doses of indirect and direct digital cephalometric radiography. *Br Dent J* 2004;197:149–52.
45. Gijbels F, Sanderink G, Wyatt J, Van Dam J, Nowak B, Jacobs R. Radiation doses of collimated vs non-collimated cephalometric exposures. *Dentomaxillofac Radiol* 2003;32:128–33.
46. Lee B, Shin G, Kang S, Shin B, Back I, Park H, et al. Dose evaluation of selective collimation effect in cephalography by measurement and Monte Carlo simulation. *Radiat Prot Dosimetry* 2012;148:58–64.
47. Loubele M, Bogaerts R, Van Dijck E, Pauwels R, Vanheusden S, Suetens P, et al. Comparison between effective radiation dose of CBCT and MSCT scanners for dentomaxillofacial applications. *Eur J Radiol* 2009;71:461–8.
48. Hirsch E, Wolf U, Heinicke F, Silva MA. Dosimetry of the cone beam computed tomography Veraviewepocs 3D compared with the 3D Accuitomo in different fields of view. *Dentomaxillofac Radiol* 2008;37:268–73.
49. Lofthag-Hansen S, Thilander-Klang A, Ekestubbe A, Helmrot E, Grondahl K. Calculating effective dose on a cone beam computed tomography device: 3D Accuitomo and 3D Accuitomo FPD. *Dentomaxillofac Radiol* 2008;37:72–9.
50. Suomalainen A, Kiljunen T, Käser Y, Peltola J, Kortensniemi M. Dosimetry and image quality of four dental cone beam computed tomography scanners compared with multislice computed tomography scanners. *Dentomaxillofac Radiol* 2009;38:367–78.
51. Pauwels R, Beinsberger J, Collaert B, Theodorakou C, Rogers J, Walker A, et al. Effective dose range for dental cone beam computed tomography scanners. *Eur J Radiol* 2012;81:267–71.
52. Theodorakou C, Walker A, Horner K, Pauwels R, Bogaerts R, Jacobs R. Estimation of paediatric organ and effective doses from dental cone beam CT using anthropomorphic phantoms. *Br J Radiol* 2012;85:153–60.
53. Qu XM, Li G, Ludlow JB, Zhang ZY, Ma XC. Effective radiation dose of ProMax 3D cone-beam computerized tomography scanner with different dental protocols. *Oral Surg Oral Med Oral Pathol Oral Radiol Endod* 2010;110:770–6.
54. Ludlow JB, Ivanovic M. Comparative dosimetry of dental CBCT devices and 64-slice CT for oral and maxillofacial radiology. *Oral Surg Oral Med Oral Pathol Oral Radiol Endod* 2008;106:106–14.

55. Davies J, Johnson B, Drage N. Effective doses from cone beam CT investigation of the jaws. *Dentomaxillofac Radiol* 2012;41:30–6.
56. Jadu F, Yaffe MJ, Lam EW. A comparative study of the effective radiation doses from cone beam computed tomography and plain radiography for sialography. *Dentomaxillofac Radiol* 2010;39:257–63.
57. Librizzi ZT, Tadinada AS, Valiyaparambil JV, Lurie AG, Mallya SM. Cone-beam computed tomography to detect erosions of the temporomandibular joint: Effect of field of view and voxel size on diagnostic efficacy and effective dose. *Am J Orthod Dentofacial Orthop* 2011;140:e25–30.
58. Tsiklakis K, Donta C, Gavala S, Karayianni K, Kamenopoulou V, Hourdakis CJ. Dose reduction in maxillofacial imaging using low dose cone beam CT. *Eur J Radiol* 2005;56:413–7.
59. Silva MA, Wolf U, Heinicke F, Bumann A, Visser H, Hirsch E. Cone-beam computed tomography for routine orthodontic treatment planning: a radiation dose evaluation. *Am J Orthod Dentofacial Orthop* 2008;133:640.e1–5.
60. Health Protection Agency Working Party on dental cone beam CT equipment. Guidance on the safe use of dental cone beam CT (computed tomography) equipment. HPA–CRCE–010. Chilton: HPA;2010.
61. Qu X, Li G, Zhang Z, Ma X. Thyroid shields for radiation dose reduction during cone beam computed tomography scanning for different oral and maxillofacial regions. *Eur J Radiol* 2012;81:376–80.
62. Rustemeyer P, Streubühler U, Suttmoeller J. Low-dose dental computed tomography: significant dose reduction without loss of image quality. *Acta Radiol* 2004;45:847–53.
63. Fanucci E, Leporace M, Di Costanzo G, Fiaschetti V, Simonetti G. Multidetector CT and dentascanner software: dosimetric evaluation and technique improvement. *Radiol Med* 2006;111:130–8.
64. Cohnen M, Kemper J, Möbes O, Pawelzik J, Mödler U. Radiation dose in dental radiology. *Eur Radiol* 2002;12:634–7.
65. Wall B, Haylock R, Jansen J, Hillier M, Hart D, Shrimpton P. Radiation risks from medical x-ray examinations as a function of the age and sex of the patient. HPA–CRCE–028. Chilton: HPA; 2011.
66. Protection of pregnant patients during medical exposures to ionising radiation advice from the Health Protection Agency. Royal College of Radiologists and College of Radiographers. Chilton: HPA; 2009.
67. Holroyd JR, Gulson AD. The radiation protection implications of the use of cone beam computed tomography in dentistry – what you need to know. Chilton: HPA; 2009.
68. Martin CJ. Effective dose: how should it be applied to medical exposure. *Brit J Radiol* 2007;80:639–647.
69. Napier ID. Reference doses for dental radiography. *Br Dent J* 1999;186:392–6.
70. Hart D, Hillier MC, Wall BF. National reference doses for common radiographic, fluoroscopic and dental x-ray examinations in the UK. *Br J Radiol* 2009;82:1–12.
71. Department of Health. The Ionising Radiations Regulations 2017. London, DH; 2017.
72. Department of Health. The Ionising Radiation (Medical Exposure) Regulations 2017. London: Department of Health; 2017.
73. Holroyd JR. National reference doses for dental cephalometric radiography. *Br J Radiol* 2011;84:1121–24.
74. Holroyd JR, Walker A. Recommendations for the design of x-ray facilities and the quality assurance of dental cone beam CT systems. A report of the HPA working party on dental cone beam CT. HPA–RPD–065. Chilton: HPA; 2011.

75. Watson SJ, Jones AL, Oatway WB, Hughes JS. Ionising radiation exposure of the UK population: 2005 Review. HPA–RPD–001. Chilton: HPA; 2005.
76. Liu H, Zhuo W, Chen B, Yi Y, Li D. Patient doses in different projections of conventional diagnostic x-ray examinations. *Radiat Prot Dosimetry* 2008;132:334–8.
77. Hirofujii Y, Aoyama T, Koyama S, Kawaura C, Fujii K. Evaluation of patient dose for barium enemas and CT colonography in Japan. *Br J Radiol* 2009; 82:219–27.
78. Mori S, Nishizawa K, Kondo C, Ohno M, Akahane K, Endo M. Effective doses in subjects undergoing computed tomography cardiac imaging with the 256-multislice CT scanner. *Eur J Radiol* 2008;65:442–8.
79. Office for National Statistics. Births and deaths in England and Wales, 2009. Newport: Office for National Statistics; 2010. Available via: www.ons.gov.uk. Accessed: July 2012.
80. Berrington de González A, Darby S. Risk of cancer from diagnostic x-rays: estimates for the UK and 14 other countries. *Lancet* 2004;363:345–51.
81. Hart D, Wall BF. UK population dose from medical x-ray examinations. *Eur J Radiol* 2004;50:285–91.
82. Davies C, Grange S and Trevor MM. Radiation protection practices and related continuing professional education in dental radiography. *Radiography* 2005;11: 255–61.
83. Tugnait A, Clerehugh V and Hirschmann PN. Radiographic equipment and techniques used in general dental practice. A survey of general dental practitioners in England and Wales. *J Dent* 2003;31:197–203.
84. Rushton VE, Horner K, Worthington HM. The quality of panoramic radiographs in general dental practice. *Br Dent J* 1999;186:630–633.
85. Helminen SE, Vehkalahti M, Wolf J and Murtomaa H. Quality evaluation of young adults’ radiographs in Finnish public oral health service. *J Dent* 2000;28:549–55.
86. [R] Rushton VE, Horner K. The use of panoramic radiology in dental practice. *J Dent* 1996;24:185–201.
87. Taylor-Weetmann K, Wake B and Hyde C. Comparison of panoramic and bitewing radiography for the detection of dental caries: a systematic review of diagnostic tests. Database of Abstracts and Reviews of Effects (DARE); 2002. Available at: http://rep.bham.ac.uk/pdfs/2002/dental_caries.pdf. Accessed: 2012.
88. Kim T-S, Obst C, Zehaczek S and Geenen C. Detection of bone loss with different x-ray techniques in periodontal patients. *J Periodontol* 2008;79:1141–9.
89. Pepelassi EA, Tsiklakis K and Diamanti-Kipiotti A. Radiographic detection and assessment of the periodontal endosseous defects. *J Clin Periodontol* 2000;27:224–30.
90. Rushton VE, Horner K, Worthington HV. Screening panoramic radiology of adults in general dental practice: radiological findings. *Br Dent J* 2001;190:495–501.
91. Brooks SL, Cho SY. Validation of a specific criterion for dental radiography. *Oral Surg Oral Med Oral Pathol* 1993;75:383–6.
92. Rushton VE, Horner K, Worthington HV. Screening panoramic radiography of new adult patients in general dental practice: diagnostic yield when combined with bitewing radiography and identification of selection criteria. *Br Dent J* 2002;192:275–9.
93. Rushton VE, Horner K, Worthington HV. Routine panoramic radiography of new adult patients in general dental practice: relevance of diagnostic yield to treatment and identification of radiographic selection criteria. *Oral Surg Oral Med Oral Pathol Oral Radiol Endod* 2002;93:488–95.
94. Bohay RN, Stephens RG, Kogon SL. A study of the impact of screening or selective radiography on the treatment and post delivery outcome for edentulous patients. *Oral Surg Oral Med Oral Pathol*

Oral Radiol Endod 1998;86:353–359.

95. Atchinson KA. Radiographic examinations of orthodontic educators and practitioners. *J Dent Educ* 1986;50:651–655.
96. Bruks A, Enberg K, Nordqvist I, Hansson AS, Jansson L, Svenson B. Radiographic examinations as an aid to orthodontic diagnosis and treatment planning. *Swed Dent J* 1999;23:77–85.
97. Han UK, Vig KWL, Weintraud JA, Vig PS, Kowalski CJ. Consistency of orthodontic treatment decisions relative to diagnostic records. *Am J Orthop Dentofac Orthop* 1991;100:212–219.
98. Atchinson KA, Luke LS, White SC. Contribution of pretreatment radiographs to orthodontists' decision making. *Oral Surg Oral Med Oral Pathol* 1991;71:238–245.
99. Atchinson KA, Luke LS, White SC. An algorithm for ordering pretreatment orthodontic radiographs. *Am J Orthod Dentofac Orthop* 1992;102:29–44.
100. Hintze H, Wenzel A, Williams S. Diagnostic value of clinical examination for the identification of children in need of orthodontic treatment compared with clinical examination and screening pantomography. *Eur J Orth.* 1990;12:385–388.
101. British Orthodontic Society. Isaacson KG, Thom AR, Atack NE, Horner K and Whaites E, editors, 4th ed. Guidelines for the use of radiographs in clinical orthodontics. London: British Orthodontic Society; 2015.
102. Scottish Intercollegiate Guidelines Network. Management of unerupted and impacted third molar teeth. Edinburgh: SIGN; 1999.
103. Lund TM and Manson-Hing LR. Relations between tooth positions and focal troughs of panoramic machines. *Oral Surg Oral Med Oral Pathol* 1975;39:318–28.
104. Scarfe WC and Farman AG. Characteristics of the Orthopantomograph OP 100. *Dentomaxillofac Radiol* 1998;27:51–7.
105. Flygare L and Öhman A. Preoperative imaging procedures for lower wisdom teeth removal. *Clin Oral Invest* 2008;12:291–302.
106. Guss DA, Clark RF, Peitz T, Taub M. Pantomography vs mandibular series for the detection of mandibular fractures. *Acad Emerg Med* 2000;7:141–145.
107. Nair MK, Nair UP. Imaging of mandibular trauma: ROC analysis. *Acad Emerg Med* 2001;8:689–695.
108. Markowitz BL, Sinow JD, Kawamoto HK Jr., Shewmake K, Khoumehar F. Prospective comparison of axial computed tomography and standard and panoramic radiographs in the diagnosis of mandibular fractures. *Ann Plast Surg* 1999;42:163–169.
109. Wilson IF, Lokesh A, Benjamin CI, Hilger PA, Hamler DD, Ondrey FG et al. Contribution of conventional axial computed tomography (nonhelical), in conjunction with panoramic tomography (zonography), in evaluating mandibular fractures. *Ann Plastic Surg* 2000;45:415–421.
110. Schimming R, Eckelt U, Kittner T. The value of computer tomograms in fractures of the mandibular condylar process. *Oral Surg Oral Med Oral Pathol Oral Radiol Endod.* 1999;87:632–639.
111. Epstein JB, Caldwell J, Black G. The utility of panoramic imaging of the temporomandibular joint in patients with temporomandibular disorders. *Oral Surg Oral Med Oral Pathol Oral Radiol Endod* 2001;92:236–239.
112. McNeill C, Mohl ND, Rugh JD, Tanaka TT. Temporomandibular disorders: diagnosis, management, education, and research. *J Am Dent Assoc* 1990;120:253–263.
113. Brooks SL, Brand JW, Gibbs SJ, Hollender L, Lurie AG, Omnell K-A et al. Imaging of the temporomandibular joint. A position paper of the American Academy of Oral and Maxillofacial Radiology. *Oral Surg Oral Med Oral Pathol Oral Radiol Endod* 1997;83:609–618.

3.1 INTRODUCTION

Allan Thom and Keith Isaacson

This section has been divided into early and late mixed dentition stages. Each section considers common clinical problems that may require radiographic examination. The section does not aim to present a comprehensive consideration of radiographic selection criteria for the specialist orthodontist, for whom a well-referenced and detailed document is available.¹ Thus, references in this section are restricted to existing guidelines.

The need to expose children to dental radiographs must be carefully considered as they are particularly susceptible to the effects of ionising radiation (see Section 2). There must be a sound clinical indication to justify exposure. There are, however, many developmental abnormalities where interceptive treatment may prevent or ameliorate later problems.

A careful clinical examination should indicate the most appropriate radiograph required to confirm the diagnosis. Wherever possible, previous radiographs (such as bitewings) should be examined to ensure that sufficient information is not already available. It should be remembered that an intraoral radiograph gives the lowest dose and should be used whenever practicable. As a result of findings from an intraoral radiograph, a panoramic radiograph may subsequently be necessary. For general dental practitioners, the decision to undertake a comprehensive radiographic examination may best be referred to a specialist orthodontist.

Cone beam computed tomography (CBCT) is becoming increasingly available to provide a three-dimensional image. However, its use in the developing dentition should adhere strictly to appropriate selection criteria, such as those developed using a formal methodology on a European basis.² Only in a very small number of cases will CBCT be required subsequent to abnormal findings identified in a conventional image. The decision to undertake CBCT would best be made by a specialist orthodontist.

3.2 EARLY MIXED DENTITION

3.2.1 *Upper labial segment*

CENTRAL INCISORS (Figure 3.1)

Frequently, an upper central incisor may erupt in cross bite with the lower incisors. This should be corrected orthodontically and can often be treated without the need for radiographs.

Failure of eruption of one or both central incisors, or retention of the deciduous incisors beyond the normal age range, requires investigation. The common causes of failure of eruption are a history of trauma or the presence of supernumerary teeth.

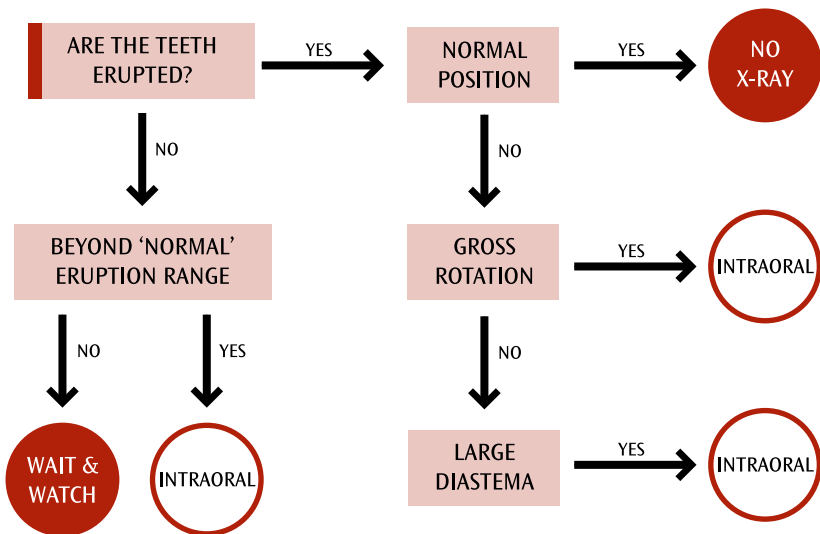


Figure 3.1: *Upper central incisors*

An intraoral radiograph will assist in making a diagnosis.

Gross rotation of one or both central incisors or an excessively large median diastema may also suggest an unerupted supernumerary.

LATERAL INCISORS (Figure 3.2)

Abnormalities in the lateral incisor region are frequently encountered. The most common abnormality is failed eruption or peg-shaped morphology. Failed eruption may be due to developmental absence of the lateral incisor. An intraoral radiograph is indicated in this instance. If the lateral incisor is missing, it is wise to determine if other successional teeth are developmentally absent, so a panoramic radiograph would be appropriate. A peg-shaped lateral incisor or one of abnormal morphology may be associated with an unerupted, misplaced canine and in this case, following palpation, if the patient's dental development age is clinically assessed to be over nine years, an intraoral radiograph may be indicated. For each of these findings, appropriate interceptive action may be required.

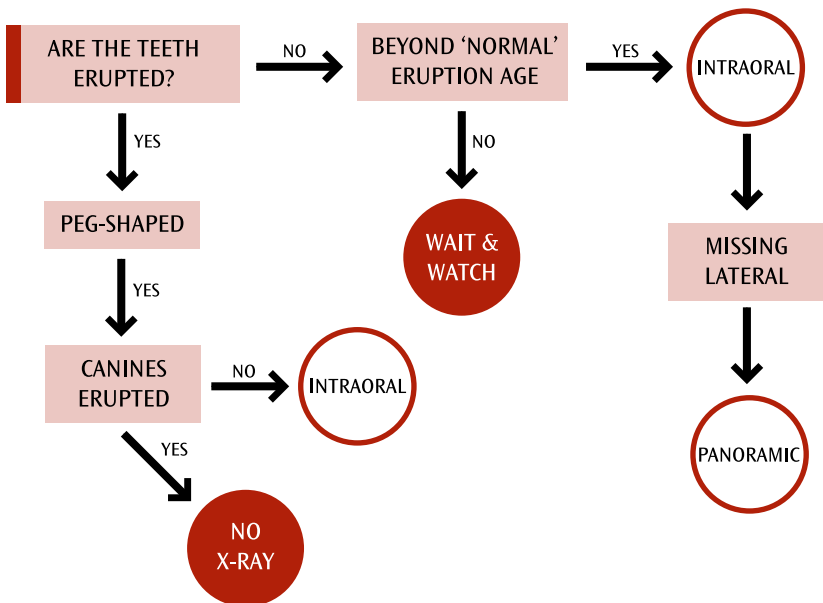


Figure 3.2: Upper lateral incisors

3.2.2 Lower labial segment (Figure 3.3)

Minor irregularities of alignment following eruption of the lower incisors are a common cause of parental concern and do not require radiographic investigation. However, significant delay in eruption of one or more of the lower incisors associated with retained deciduous predecessors will require radiographic investigation.

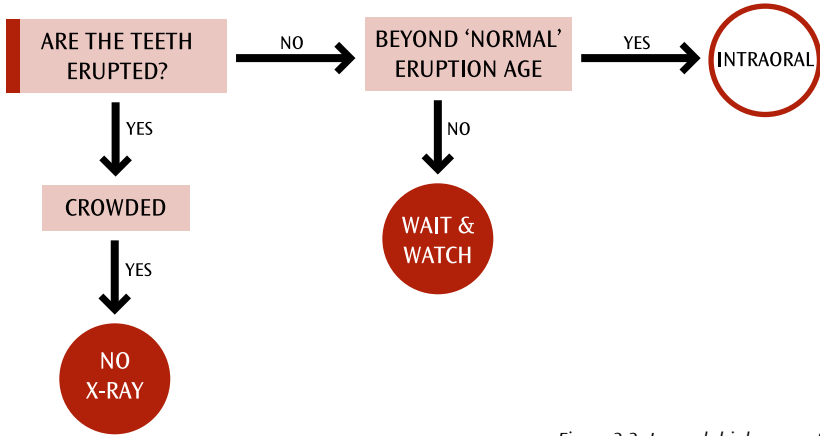


Figure 3.3: Lower labial segment



When investigating developmental disturbances of teeth in the early mixed dentition stage, intraoral radiography should be considered.

3.2.3 Posterior segments

CROSS BITES

Unilateral posterior cross bites in the early mixed dentition associated with a displacing activity may be corrected with simple orthodontic appliances. In the absence of any other adverse clinical indicators, this can normally be accomplished without the need for radiographs.

FIRST PERMANENT MOLARS (Figure 3.4)

When there is a doubtful prognosis for one or more permanent first molars, in a patient with a high caries incidence, it is wise to consider the possible loss of all four first molars to enable balanced development of the occlusion. A panoramic radiograph is required to determine the presence of successional teeth, particularly the second premolars. The findings may indicate the need for a specialist orthodontic opinion to plan the treatment appropriately.

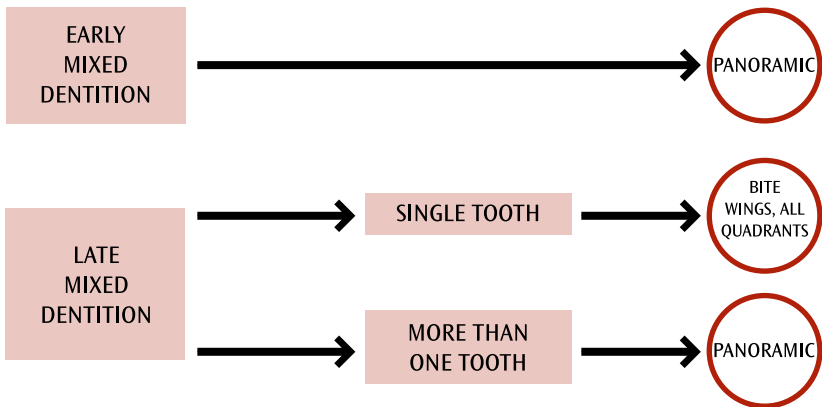


Figure 3.4: First permanent molars (poor prognosis)

Impaction of an upper first molar into the second deciduous molar necessitates an intraoral image to determine the presence of the second premolar, the absence of which may suggest the possibility of other developmentally missing teeth. Should this prove to be the case, a panoramic radiograph may be necessary.

C

When one or more first permanent molars have a doubtful prognosis, a panoramic radiograph may be justified to allow assessment of the other first molars and determine the presence of successional teeth.

3.3 LATE MIXED DENTITION

3.3.1 Labial segments

Any clinical abnormalities not identified in the early mixed dentition must be investigated. It is likely that radiographic investigation will be necessary. Figures 3.1 to 3.3 remain relevant in the late mixed dentition.

3.3.2 Canines (Figure 3.5)

An essential part of the clinical examination in the late mixed dentition is palpation of the buccal sulcus to confirm the presence and position of the unerupted maxillary canines. If the patient is 11 years old or over and the canines cannot be palpated, either buccally or palatally, an intraoral radiograph would be appropriate as early diagnosis of a misplaced canine is of utmost importance to outcome.

B

In the late mixed dentition, radiography is indicated when permanent canines cannot be palpated.

A peg-shaped lateral incisor or unilateral delayed loss of a deciduous canine may also require an intraoral radiograph in view of the association of these clinical findings with a misplaced canine.

Where there is doubt as to the viability of a lateral incisor, possibly due to resorption by a misplaced canine, identified by conventional radiography, CBCT may be indicated.²

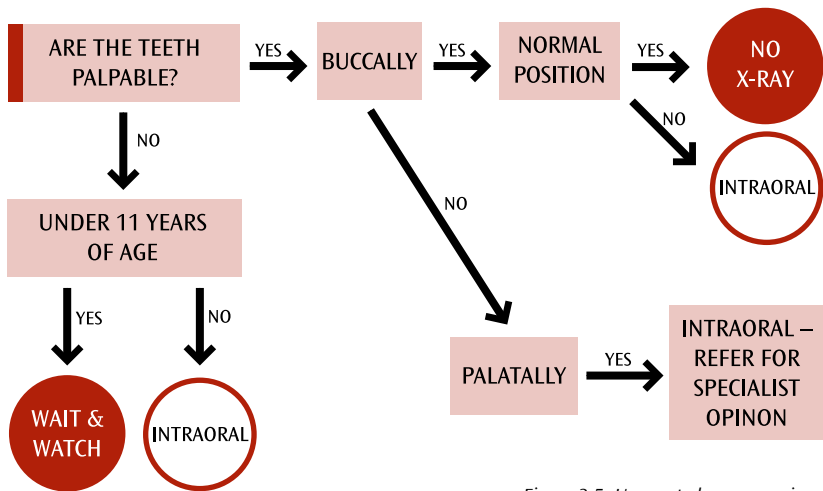


Figure 3.5: Unerupted upper canines

The use of CBCT is not indicated as a routine but only after careful examination of the existing radiographic images. Wherever possible, a limited field-of-view CBCT examination should be used as this results in a lower radiation dose.

Although misplaced maxillary canines are a commonly encountered problem, the possibility of displaced lower canines should not be overlooked. If their eruption is delayed, then radiographic investigation may be required.

C

For the assessment of an impacted tooth and possible resorption of an adjacent tooth, CBCT may be used when the information cannot be obtained adequately by lower-dose conventional radiography.

3.3.3 Deciduous molars (Figure 3.6)

Delayed loss of second deciduous molars can be an indication of developmentally absent second premolars. Examination of existing bitewing images may be adequate

to determine the presence of the second premolars. If the second deciduous molars are retained when other successional teeth have erupted, an appropriate field–limited panoramic radiograph can be used. However, when a single second deciduous molar is retained, an intraoral image may suffice. Submerging deciduous molars should be observed clinically at regular intervals. Noticeable deterioration between regular examinations may require intraoral radiography.

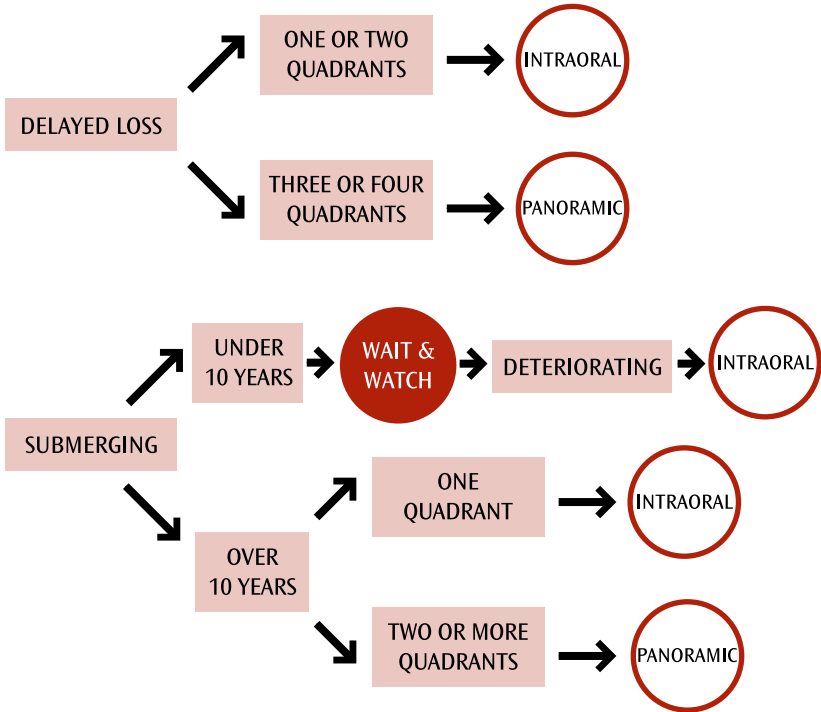


Figure 3.6: Retained deciduous molars

3.3.4 Permanent molars (Figure 3.4)

A grossly carious first molar will usually require a field-limited panoramic radiograph to assess the condition and prognosis of the other first molars and to confirm the presence of permanent successional teeth. An orthodontic opinion may be indicated where the loss of one or more first molars is necessary.

3.4 ORTHODONTIC TREATMENT

The indications for diagnostic radiographs are fully covered in the British Orthodontic Society guidelines.¹

For the GDP, if a routine dental examination indicates that an orthodontic opinion may be appropriate, then choice of radiographs should normally be left to the specialist. If a specialist orthodontic opinion is necessary as a result of a radiographic finding, it is essential that any available radiographic images accompany the referral letter.

The flow charts in this section are for general guidance only. Every patient must be assessed on their merits.

3.5 REFERENCES

1. British Orthodontic Society. Isaacson KG, Thom AR, Atack NE, Horner K and Whaites E, editors, 4th ed. Guidelines for the use of radiographs in clinical orthodontics. London: British Orthodontic Society; 2015.
2. European Commission. Radiation Protection 172. Cone beam CT for dental and maxillofacial radiology: evidence based guidelines. Luxembourg: European Commission; 2012. Available at: <https://ec.europa.eu/energy/sites/ener/files/documents/172.pdf>. Accessed: January 2018.

4

RADIOGRAPHS IN DENTAL CARIES DIAGNOSIS

4.1 INTRODUCTION

Nigel Pitts and David Ricketts

Most of the available research on radiographic diagnosis of dental caries concerns children. This may be because of the greater risks of ionising radiation in children and the historically high prevalence of caries in younger individuals, combined with a greater focus on prevention. Current thinking recognises the importance of early caries detection and preventive caries management in adults as well. In recent years there has also been an increasing emphasis on caries risk assessment, changes in caries risk and assessing the activity of individual lesions in patients of all ages. Children have been selected as a principal focus within this section due to the relative volume of evidence for the younger age groups. The methodology used to derive the recommendations that follow can be examined in Section 1.

When assessing caries risk, clinicians should note that in 2003–2004 the Guideline Development Group and the National Institute for Health and Clinical Excellence Collaborating Centre reviewed the evidence on caries risk in relation to recall frequency, leading to the issue in 2004 of *Dental Recall: Recall Interval Between Routine Dental Examinations*.¹ Readers should refer to this guidance for a checklist for assessing caries risk in relation to recall frequency. More recent consideration of personalised recall frequency and the use of bitewing radiography in lower caries risk groups can also be found by Clarkson et al (2009)² and Mejäre and Kidd (2008).³

4.2 CHILDREN

Posterior bitewing radiographs are an essential adjunct to clinical examination^{5R-8R} (one review^{6R} has been classified independently by the Scottish Intercollegiate Guidelines Network as a meta-analysis) and should be considered even for pre-school children.^{3,4} It has also become apparent that not only is the bitewing radiograph necessary for approximal caries detection, but that it can also offer a significant yield in the detection of occlusal caries.^{7R-9R}

The magnitude of the increased diagnostic yield from the use of radiography on occlusal surfaces is related to the method of clinical visual assessment employed. Meticulous visual assessment of clean dry teeth with criteria such as ICDAS¹⁰⁻¹¹ can disclose many lesions which would be otherwise missed. The periodic bitewing examination can contribute to an individual's care plan for preventive and operative dental care.¹² Information about lesion behaviour over time (progression, arrest, regression) can be added to the caries status assessment made at the first visit and can contribute to an appraisal of the patient's response to preventive therapy.

Although there is a need to ensure that radiographic exposures are kept as low as reasonably practicable, this concern must be carefully balanced against the ethical difficulties of failing to employ a diagnostic aid that has been shown to detect clinically important numbers of lesions that would otherwise remain hidden. Even when approximal contacts are open, bitewing radiographs have a role in identifying occlusal lesions. The importance of a high-quality, standardised technique, using image receptor-holding and beam-aiming devices and ensuring proper processing, cannot be over-emphasised. Increased use of digital radiography overcomes some of the errors previously associated with the processing of conventional radiographic films.

A patient should only be exposed to ionising radiation after a thorough clinical examination. This should include an assessment of caries risk as high, medium or low. Appendix 2 lists some of the many factors that a practitioner will consider in making a caries risk assessment. The importance of the individual factors will vary from patient to patient and it must be remembered that risk status may change over time.

This assessment of risk is central to deciding when to take subsequent radiographs.^{5R,8R,13R–15R} This time interval will vary widely but it should be specific to each patient. Although reliable risk assessment can be problematic, clinicians are particularly good at identifying high-risk individuals.

B In the diagnosis of caries in children, the weight of expert opinion supports the statement that caries should be diagnosed as early as possible to allow management before cavitation and pulpal involvement, and to identify caries-active patients and those at increased risk of caries in the future.⁴

C The taking of 'routine' radiographs based solely on time elapsed since the last examination is not supportable.^{15R,16} Intervals between subsequent radiographic examinations must be reassessed for each new period as individuals can move in and out of caries risk categories over time.

4.2.1 Caries risk assessment

The evidence around caries risk assessment is complex, and a number of systematic reviews have been summarised by Twetman and Fontana (2009).¹⁷ There are multiple risk factors and indicators which carry a range of weightings. The strength of evidence varies between children and adults. For all ages, by far the most important factor is past caries experience. While the evidence supporting the use of other individual risk factors may not be strong at a group level, there is still value at the individual patient level to aid in the development of an individualised and targeted preventive and disease management plan.^{18,19}

4.2.2 High caries risk

Expert opinion supports taking bitewing radiographs at the initial examination for all children designated as being at high caries risk.^{13R,15R} In addition, there is a body of evidence to support this view.^{17,21,22R,23–26}

There is a significant diagnostic yield associated with taking bitewing radiographs for use in conjunction with clinical examination for both approximal and occlusal caries detection, even in the absence of clinically detectable decay.^{20,24,27,28}

The degree of benefit is variously reported as being between 167% and 800% of the yield from clinical diagnosis, with or without fibreoptic transillumination assistance. In adults with a history of high caries risk and previous restorative care of varying complexity, bitewing radiographs are felt to have increased importance in detecting defective/overhanging restoration margins and caries adjacent to restorations on obscured tooth surfaces.²⁹

In terms of the contribution that radiographs might make to individual patient care plans, current evidence suggests that:

- If a small lesion is detected which radiographically appears to be less than halfway through approximal enamel, the lesion's location should be recorded and periodic review arranged. Preventive treatment should be instigated.
- If an approximal lesion extending to the inner half of enamel is detected, or if an outer-half lesion is seen to progress, preventive therapy should be instigated and the results of such therapy should be periodically monitored.^{13R}
- In a high caries risk individual, approximal lesions extending into dentine, detected radiographically, have a great likelihood of exhibiting cavitation.^{23,30–32}
- Additionally, it has been demonstrated that radiographic evidence of occlusal dentine demineralisation is significantly associated with heavily infected dentine;³³ therefore, the bitewing radiograph should contribute to operative care plans for individuals with radiographic occlusal dental lesions.

B

It is recommended that all children at high caries risk have six-monthly posterior bitewing radiographs taken until no new or active lesions are apparent and the individual has entered another risk category.*

* Bitewings should not be taken more frequently and it is imperative to reassess caries risk in order to justify using this interval again.

It has been shown that in individuals with high caries risk, lesions can still take up to three or four years to penetrate approximal enamel in permanent teeth.^{34R} The time taken for caries to progress from the enamel-dentine junction to the pulp is unknown.^{35R} Many authors consequently recommend six-monthly radiographs for all high caries risk individuals until no new or active lesions are apparent. Again, radiographs should not be taken more frequently, and it is imperative to reassess an individual's caries risk in order to justify using this interval again.

4.2.3 Moderate caries risk

The evidence also supports the diagnostic use of bitewing radiographs for children with a moderate caries risk. Many authors report significant addition to the diagnostic yield from the use of bitewing radiographs, varying from 150% to 270% of the yield from clinical examination alone.³⁶⁻⁴³ This increased yield relates to both approximal and occlusal caries.

Of the 12 studies in this area which passed critical review, no significant diagnostic yield was gained in three (in one study on four-year-old children,⁴¹ in one where simulated clinical examination was supplemented by fibreoptic transillumination,³⁸ and in one when permanent teeth were clinically examined meticulously).⁴⁴

On balance, the evidence supports the taking of posterior bitewing radiographs annually for children who are designated as being at moderate caries risk.

B

It is recommended that all children with a moderate risk of developing caries have annual posterior bitewing radiographs taken until no new or active lesions are apparent and the patient has entered another risk category.

4.2.4 Low caries risk

Compared to the evidence regarding children with high and moderate caries risk, there is less evidence available to support the taking of posterior bitewing radiographs in children designated to be at low risk of developing caries. This may be due in part to the sample selection that many researchers have available to them, resulting in few studies in this area. The balance of the available evidence on the need to take bitewings is unclear. Although the diagnostic yield from posterior bitewing radiographs is comparatively lower than the yield from higher-risk groups,⁴⁵ high-quality studies still show a significant yield. In one study, radiographs revealed two to three times more carious lesions than clinical examination alone.⁴⁵

The evidence reviewed suggests that:

- Even in low caries regions, selective radiography should be conducted on surfaces that are clinically suspected to be carious.⁴⁶ There is continuing concern that hidden dentinal caries may affect significant numbers of low caries risk individuals,^{3,47R} although there is a lack of high-quality studies on the prevalence of hidden dentinal caries in low caries risk populations.
- In the primary dentition, detection of three or more discoloured enamel lesions or dentinal lesions has been claimed to be a good predictor of the presence of additional dentinal lesions on radiograph, which could not be detected by visual examination.⁴⁸
- In low caries risk groups, the time taken for approximal enamel lesions to progress through to dentine in permanent teeth is now in excess of six to eight years on average, and clinical decisions to restore must reflect this slow progression.^{47R}

- There are particular problems associated with assessing sealed occlusal surfaces in children with low caries risk; bitewing radiographs can provide a significant diagnostic yield, if used appropriately.⁴⁹

In the low caries risk category, it is therefore important for individual clinicians to apply risk-benefit calculations to each of their patients in order to make appropriate decisions.

A child patient with little or no caries activity does not require bitewing radiographs at every recall appointment;^{14R} however, it is important to reconsider the child's caries risk status.

B

The weight of expert opinion supports the view that children with low caries risk should be radiographed at approximately 12 to 18-month intervals in the primary dentition and at approximately two-year intervals in the permanent dentition. More extended radiographic recall intervals may be appropriate if there is specific evidence of continuing low caries risk.^{15R,35R}

4.3 ADULTS

There is comparatively little evidence evaluating the present diagnostic yield of radiographs for caries in adults. It must be appreciated, however, that the carious process and caries activity are dependent upon interactions on a susceptible tooth surface of bacterial plaque with appropriate sugary substances, and that these factors far outweigh a patient's chronological age. In the absence of experimental data from older age groups, it is reasonable, therefore, to extrapolate from the information available from studies of children and young adults.

There are particular reasons to be cautious in assessment of caries and caries risk in adults. As a consequence of the genuine overall reduction of caries prevalence across the UK population, when caries is present it often progresses very slowly and can present very late; thus cavitation into dentine may be visible for the first time in young adults who appear to be caries-free. Similarly, caries risk assessments of adults must consider rapid behaviour and lifestyle changes that can have a significant dental impact. Changes in caries risk may follow the patient becoming less dextrous in plaque removal, a reduction in saliva following the use of some medications or the onset of Sjögren's syndrome, and/or dietary changes following events such as retirement, bereavement or a change in social environment. Thus, while interpretation of the clinical examination and social history must be tailored to the age of the patient and the circumstances indicating the need for the clinical examination, the diagnostic benefits and limitations of dental radiography for adults are essentially comparable with those for children.

Overall, root caries is a growing problem for only a minority of adults, but an increasing proportion of this population are elderly patients. One specific clinical issue concerns root caries related to impacted third molar teeth and distal surface caries in second molar teeth. There is comparatively little evidence regarding radiographic selection criteria in relation to root caries. Care should always be taken to differentiate radiographic signs of root caries from artefacts such as cervical burnout.

For these reasons, while suggesting that high-quality studies with adults are needed, the same recommendations as made for children are made for adults.

4.3.1 High caries risk

C It is recommended that all adults designated as having high caries risk have six-monthly posterior bitewing radiographs taken until no new or active lesions are apparent and the individual has entered another risk category.*

*Bitewings should not be taken more frequently and it is imperative to reassess caries risk in order to justify using this interval again. It is also important to remember that the rate of caries progression in enamel and dentine will differ and that progression rates in adults may well be slower than in children.

4.3.2 Moderate caries risk

C It is recommended that all adults designated as having moderate caries risk have annual posterior bitewing radiographs taken until no new or active lesions are apparent and the individual has entered another risk category.

4.3.3 Low caries risk

C It is recommended that adults designated as having low caries risk have posterior bitewing radiographs taken approximately every two years. More extended radiographic recall intervals may be employed if there is explicit evidence of continuing low caries risk.

4.4 DIGITAL DENTAL RADIOGRAPHY

Over the last decade, digital radiography has seen increasing use in general practice and is set to become the default system for new installations. Its benefits range from the potential to reduce x-ray exposures (although faster film has to an extent reduced this benefit), eliminate conventional processing faults, allows the manipulation of images (contrast enhancement) and facilitate sharing and transfer of information, enabling the efficient storage of images. The comparative diagnostic yield with conventional film radiography has been shown to be broadly equivalent.⁵⁰

Digital x-ray equipment can now be regarded as standard for contemporary dental practice.

4.5 NEWER RADIOGRAPHIC METHODS AND ALTERNATIVES

TO RADIOGRAPHS FOR CARIES DIAGNOSIS

There is a considerable body of evidence relating to both children and adults looking at new methods as adjuncts and alternatives to radiographic caries diagnosis;^{51R} however, this area is complex as the differing methodologies used often confound direct comparisons.^{8R,47R,52-54}

4.5.1 Cone beam computed tomography (CBCT)

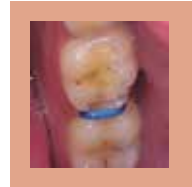While three-dimensional imaging is of clinical significance in many fields, its use in caries diagnosis is not currently supported in a European guideline document.^{55R} In practice, CBCT gives the advantage of three dimensions at the expense of a loss of resolution, when compared with intraoral radiography. There are significant problems with CBCT related to artefacts, principally from metallic restorations in the path of the x-ray beam. These artefacts introduce dark streaks that pass through the crowns of other teeth, leading to artefactual radiolucencies which can produce a caries-like appearance, or even mask real carious lesions.

B

CBCT should not be used as a routine method of caries diagnosis.

4.5.2 Elective temporary tooth separation

Elective temporary tooth separation (using orthodontic elastics between teeth) has been advocated as a method of assessing directly the caries status of approximal surfaces. The method currently requires an interval of one to seven days before the approximal surfaces can be viewed.^{44,56-58}



This method is particularly useful in determining whether or not cavitation has taken place.^{31,58,59} In situations where confirmation of cavitation is difficult, use of a light-bodied silicone impression material interdentally is of benefit in visualising surface status. Separation has been used successfully in Scotland, England, Brazil, Denmark and Sweden, and has been shown to be a viable tool in a general dental practice setting.⁴⁴ Current research is exploring the use of approximal sealants for caries management and this technique also uses elective tooth separation.

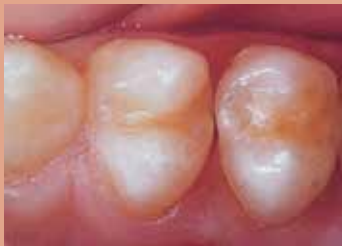

Figure 4.1 Contact area of premolars showing possible caries approximally.

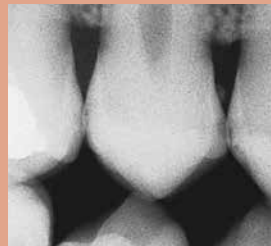

Figure 4.2 Part of a bitewing radiograph showing equivocal lesions approximally.

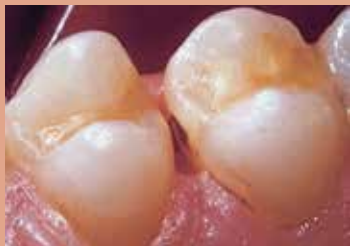

Figure 4.3 Following temporary elective tooth separation, the presence or absence of cavitation can be determined by direct visual examination.

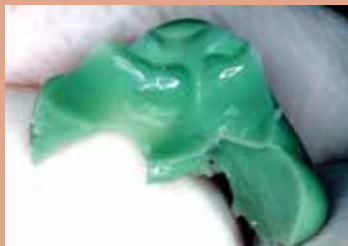

Figure 4.4 Silicone impression material can be used to confirm cavitation or surface discontinuity.

C

Consideration should be given to temporarily separating approximal surfaces where there is doubt whether or not cavitation has taken place and thus whether a filling is indicated.

4.5.3 Fibreoptic transillumination

For many years there has been debate in the literature about the potential diagnostic use of fibreoptic transillumination (FOTI), either to replace or supplement bitewing radiographs (Figures 4.5–7).^{40,60R} The balance of evidence suggests that it is an important adjunct which has considerable diagnostic value for detecting dentinal lesions at approximal sites. Bitewing radiographs will detect more dentinal lesions and many more ‘enamel’ lesions than FOTI (even though radiographs will still not detect all approximal enamel lesions). Research results with FOTI are obtained using custom-made 0.5 mm diameter tips in the hands of examiners trained in the use of this somewhat technique-sensitive method.

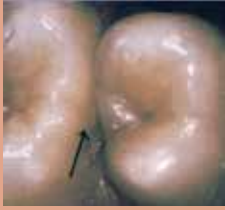

Figure 4.5 Clinically suspicious mesial surface of upper 6.



Figure 4.6 FOTI reveals a shadow within the mesial surface of the upper 6.

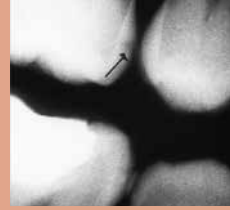

Figure 4.7 Part of a bitewing radiograph reveals a lesion in the mesial surface of the upper 6.

C

FOTI should be used as an adjunct to bitewing radiographs for caries diagnosis. When used, a 0.5 mm tip should be employed and training is recommended.

4.5.4 Electrical methods of caries diagnosis

Of the 'new' methods of caries diagnosis, there is a growing consensus that electrical methods provide the most promising results and the greatest potential for helping practitioners faced with the difficult task of diagnosing caries without using ionising radiation.^{47R, 52, 61–63} Two basic systems have been developed, one based on fixed low-frequency AC and a co-axial air supply,⁶¹ and one based on AC impedance spectroscopy.⁶⁴ Research into the latter has led to the commercial introduction of a caries detection device (CarieScan). This is an area where progress can be anticipated.

C

The development, testing and implementation of electrical detection and monitoring aids should be followed closely.

4.5.5 Laser fluorescence methods

Research into laser fluorescence has led to the development of commercially available devices such as the DIAGNOdent and DIAGNOdent pen (KaVo, Biberach, Germany) and VistaProof (Dürr, Bietigheim-Bissingen, Germany). The former detects fluorescence from bacterial by-products, namely porphyrins. Research into the DIAGNOdent has shown that specificity (false-positive decisions) is a particular problem.⁶⁵ Such decisions could lead to over-treatment and clinicians should be aware of this potential problem.

C

Care should be taken in the interpretation of results using some optical caries detection devices as false positives can pose a problem.

4.5.6 Quantitative laser fluorescence

Sound tooth tissue fluoresces under laser light of a specific wavelength, while the intensity of fluorescence decreases in carious lesions. The intensity of fluorescence can be quantified and is the basis for this detection technique, also referred to as quantitative light-induced fluorescence (QLF), which is still in its research stage.

4.6 REFERENCES

1. National Institute for Health and Clinical Excellence. Dental recall: recall interval between routine dental examinations. London: NICE; 2004. Available at: <http://guidance.nice.org.uk/CG19/Guidance/pdf/English>. Accessed: May 2004.
2. Clarkson JE, Amaechi BT, Ngo H. Recall, reassessment and monitoring. In Pitts NB. Detection, assessment, diagnosis and monitoring of caries. Basel: Karger; 2009.
3. Mejäre I, Kidd EAM. Radiography for caries diagnosis. In Fejerskov O, Kidd E. Dental caries: The disease and its clinical management. 2nd edition. Munksgaard: Blackwell; 2008. p69–88.
4. Scottish Intercollegiate Guidelines Network. Prevention and management of dental decay in the pre-school child. SIGN Guideline 83. Edinburgh: SIGN; 2005. Available at: www.sign.ac.uk/pdf/sign83.
5. [R] Hanlon PM. Radiographic considerations in pedodontics. *J Pedodont* 1985;9:285–301.
6. [R] Kidd EA, Pitts NB. A reappraisal of the value of the bitewing radiograph in the diagnosis of posterior approximal caries. *Br Dent J* 1990;169:195–200.
7. [R] Weerheijm KL. Occlusal 'hidden caries'. *Dent Update* 1997;24:182–4.
8. [R] Pitts NB. The use of bitewing radiographs in the management of dental caries: scientific and practical considerations. *Dentomaxillofac Radiol* 1996;25:5–16.
9. [R] Henderson NJ, Crawford PJM. Guidelines for taking radiographs of children. *Dent Update* 1995;22: 158–61.
10. ICDAS Foundation. International Caries Detection and Assessment System. Available at: www.ICDAS.org.
11. Pitts NB, Ekstrand KR. International Caries Detection and Assessment System (ICDAS) and its International Caries Classification and Management System (ICCMS™) – methods for staging of the caries process and enabling dentists to manage caries. *Com Dent Oral Epidemiol* 2013;41:41–52.
12. Pitts NB. Detection, assessment, diagnosis and monitoring of caries. Basel: Karger; 2009.
13. [R] Pitts NB. The bitewing examination as a preventive aid to the control of approximal caries. *Clin Prev Dent* 1984;6:12–5.
14. [R] Howard HE. Rethinking pedodontic radiology. *J Dent Child* 1981;48:192–7.
15. [R] Nowak AJ, Miller JW. High yield pedodontic radiology. *Gen Dent* 1985;33:45–7.
16. Pitts NB. Score system for monitoring the behaviour of radiologically diagnosed approximal carious lesions. *Community Dent Oral Epidemiol* 1985;13:268–72.
17. Twetman S, Fontana M. Patient caries risk assessment. In Pitts NB. Detection, assessment, diagnosis and monitoring of caries. Basel: Karger; 2009. p.91-101
18. Schutte AG, Pitts NB, Huysmans MC, Splieth C, Buchalla W. European core curriculum in cariology for undergraduate dental students. *Eur J Dent Educ* 2011;15(suppl.):9-17.
19. Ismail AL et al. Caries management pathways preserve dental tissues and promote oral health. *Community Dent Oral Epidemiol* 2013;41:12–40.
20. Stephen KW, Russell JI, Creanor SL, Burchell CK. Comparison of fibre optic transillumination with clinical and radiographic caries diagnosis. *Community Dent Oral Epidemiol* 1987;15:90–4.
21. Stephens RG, Kogon SL, Wainright RJ, Reid JA. Information yield from routine bitewing radiographs for young adults. *Can Dent Assoc* 1981;47:247–52.
22. [R] Wenzel A, Pitts NB, Verdonshot EH, Kalsbeek H. Developments in radiographic caries diagnosis. *J Dent* 1993;21:131–40.
23. de Araujo FB, Rosito DB, Toigo E, dos Santos CK. Diagnosis of approximal caries: Radiographic versus clinical examination using tooth separation. *Am J Dent* 1992;5:245–8.
24. Creanor SL, Russell JI, Strang DM, Stephen KW, Burchell CK. The prevalence of clinically undetected occlusal dentine caries in Scottish adolescents. *Br Dent J* 1990; 169:126–9.

25. Nytnun RB, Raadal M, Espelid I. Diagnosis of dentin involvement in occlusal caries based on visual and radiographic examination of the teeth. *Scand J Dent Res* 1992;100:144–8.
26. Lussi A. Impact of including or excluding cavitated lesions when evaluating methods for the diagnosis of occlusal caries. *Caries Res* 1996;30:389-93.
27. Ketley C, Holt R. Visual and radiographic diagnosis of occlusal caries in first permanent molars and in second primary molars. *Br Dent J* 1993;174:64–70.
28. Wenzel A Larsen MJ, Fejerskov O. Detection of occlusal caries without cavitation by visual inspection, film radiographs, xeroradiographs, and digitized radiographs. *Caries Res* 1991;25:365–71.
29. Levin L, Coval M, Geiger SB. Cross-sectional radiographic survey of amalgam and resin-based composite posterior restorations. *Quintessence Int* 2007;38(6):511–4.
30. Espelid I, Tveit AB. Clinical and radiographic assessment of approximal carious lesions. *Acta Odontol Scand* 1986;44:31–7.
31. Lunder N, von der Fehr FR. Approximal cavitation related to bite-wing image and caries activity in adolescents. *Caries Res* 1996;30:143–7.
32. Kidd EAM, van Amerongen JP, van Amerongen WE. The role of operative treatment in caries control. In Fejerskov O, Kidd E. *Dental Caries. The disease and its clinical management*. 2nd edition. Munksgaard: Blackwell; p357–365.
33. Ricketts DNJ, Kidd EAM, Beighton D. Operative and microbiological validation of visual, radiographic and electronic diagnosis of occlusal caries in non-cavitated teeth judged to be in need of operative care. *Br Dent J* 1995;179:214–20.
34. [R] Lervik T, Haugejorden O, Aas C. Progression of posterior approximal carious lesions in Norwegian teenagers from 1982 to 1986. *Acta Odontol Scand* 1990;48:223–7.
35. [R] Elderton RJ. Assessment and clinical management of early caries in young adults: Invasive versus non-invasive methods. *Br Dent J* 1985; 158:440–4.
36. Kidd EA, Naylor HN, Wilson RF. Prevalence of clinically undetected and untreated molar occlusal dentine caries in adolescents on the Isle of Wight. *Caries Res* 1992;26:397–401.
37. Richardson PS, McIntyre IG. The difference between clinical and bitewing detection of approximal and occlusal caries in Royal Air force recruits. *Community Dent Health* 1996;13:65–9.
38. Mann J, Pettigrew JC, Revach A, Arwas JR, Kochavi D. Assessment of the DMF-S index with the use of bitewing radiographs. *Oral Surg Oral Med Oral Pathol.* 1989;68:661–5.
39. White SC, Atchison KA, Hewlett ER, Flack VF. Efficacy of FDA guidelines for ordering radiographs for caries detection. *Oral Surg Oral Med Oral Pathol.* 1994;77:531–40.
40. Peers A. Hill FJ, Mitropoulos CM, Holloway PJ. Validity and reproducibility of clinical examination, fibre-optic transillumination, and bite-wing radiology for the diagnosis of small approximal carious lesions: an in vitro study. *Caries Res* 1993;27:307–11.
41. Steckslen-Blicks C. Wahlin Y-B. Diagnosis of approximal caries in pre-school children. *Swed Dent J* 1983;7;179–84.
42. Rimmer PA, Pitts NB. Effects of diagnostic threshold and overlapped approximal surfaces on reported caries status. *Community Dent Oral Epidemiol* 1991; 19;205–12.
43. Weerheijm KL, Groen HJ, Bast AJJ, Kieft JA, Eijkman MAJ, van Amerongen WE. Clinically undetected occlusal dentine caries: a radiographic comparison. *Caries Res* 1992;26:305–9
44. Rimmer PA, Pitts NB. Temporary elective tooth separation as a diagnostic aid in general dental practice. *Br Dent J* 1990;169:87–92.
45. Ruiken HHM, Truin GJ, Konig KG. Feasibility of radiographical diagnosis in 8-year-old

- schoolchildren with low caries activity. *Caries Res* 1982;16:398–403.
46. Hintze H. Screening with conventional and digital bite-wing radiography compared to clinical examination alone for caries detection in low-risk children. *Caries Res* 1993;27:499–504.
 47. [R] Pitts NB. Diagnostic tools and measurements impact on appropriate care. *Community Dent Oral Epidemiol* 1997;25:24–35.
 48. Roeters FJM, Verdonschot EH, Bronkhorst EM, van't Hof MA. Prediction of the need for bitewing radiography in detecting caries in the primary dentition. *Community Dent Oral Epidemiol* 1994;22:456–60.
 49. Deery C. An evaluation of the use of pit and fissure sealants in the General Dental Service in Scotland [PhD thesis]. Dundee: University of Dundee; 1997.
 50. Hintze H, Wenzel A, Frydenberg M. Accuracy of caries detection with four storage phosphor systems and E-speed radiographs. *Dentomaxillofac Radiol* 2002;31:170–5.
 51. [R] Angmar-Mansson B, ten Bosch JJ. Advances in methods for diagnosing coronal caries – a review. *Adv Dent Res* 1993;7:70–9.
 52. Twetman S, Axelsson S, Dahlén G, Espelid I, Mejäre I, Norlund A, Tranæus S. Adjunct methods for caries detection: A systematic review of literature. *Acta Odontol Scand* 2012; e-pub; 1-10.
 53. Bader JD, Shugars DA, Bonito AJ. Systematic reviews of selected dental caries diagnostic and management methods. *J Dent Educ* 2001;65:960–8.
 54. Neuhaus KW, Longbottom C, Ellwood R, Lussi A. Novel lesion detection aids. In Pitts NB. *Detection, assessment, diagnosis and monitoring of caries*. Basel: Karger; 2009.
 55. [R] European Commission. Radiation Protection 172. Cone beam CT for dental and maxillofacial radiology: evidence based guidelines. Luxembourg: European Commission; 2012. Available at: <https://ec.europa.eu/energy/sites/ener/files/documents/172.pdf> Accessed: January 2018.
 56. Pitts NB, Longbottom C. Temporary tooth separation with special reference to the diagnosis and preventive management of equivocal approximal carious lesions. *Quintessence Int*. 1987;18:563–73.
 57. Pitts NB, Rimmer PA An in vivo comparison of radiographic and directly assessed clinical caries status of posterior approximal surfaces in primary and permanent teeth. *Caries Res* 1992;26:146–52.
 58. Seddon RP. The detection of cavitation in carious approximal surfaces in vivo by tooth separation, impression and scanning electron microscopy. *J Dent* 1989;17:117.20.
 59. Danielsen B, Wenzel A, Hintze H, Nyvad B. Temporary tooth separation as an aid in the diagnosis of cavitation in approximal surfaces. *Caries Res* 1996;30:271.
 60. [R] Pine CM. Fibre-optic transillumination (FOTI) in caries diagnosis. In: Stookey G, editor. *Proceedings of the first Annual Indiana Conference; Early Detection of Dental Caries*. Indiana: Indiana University; 1996:51–65.
 61. Ricketts DNJ, Kidd EAM, Wilson RF. A re-evaluation of electrical resistance measurements for the diagnosis of occlusal caries. *Br Dent J* 1995;178:11–7.
 62. Rock WP, Kidd EAM. The electronic detection of demineralisation in occlusal fissures. *Br Dent J* 1988;164:243–7.
 63. [R] Ricketts DNJ. Electrical conduction detection methods. In: Stookey G, editor. *Proceedings of the First Annual Indiana Conference: Early Detection of Dental Caries*. Indiana: Indiana University; 1996. p.67.
 64. Longbottom C, Huysmans MC, Pitts NB, Los P, Bruce PG. Detection of dental decay and its extent using AC impedance spectroscopy. *Nat Med* 1996;2:235–7.
 65. Bader JD, Shugars DA. A systematic review of the performance of a laser fluorescence device for detecting caries. *J Am Dent Assoc* 2004;135:1413–26.

4A

ALTERNATIVE APPROACH TO RADIOGRAPHY FOR CARIES DIAGNOSIS IN CHILDREN

4A.1 THE EAPD APPROACH

Keith Horner and Ken Eaton

As highlighted in Section 4, the evidence that bitewing radiography can provide a diagnostic yield for caries over and above that obtained through clinical diagnosis alone is established, at least for high and moderate caries risk groups. However, there is uncertainty in translating this evidence into recommendations concerning specific intervals between bitewing examinations for regular patients. In this document, the editors felt that it was important to highlight an alternative approach for prescription of bitewing radiography in children, developed in 2004 by the European Academy of Paediatric Dentistry (EAPD).¹

The EAPD guidelines, based strongly on evidence from research in Scandinavian countries, reiterated that additional information on the presence and depth of caries may be obtained from bitewing radiography. To determine the interval between review bitewing examinations in children, the EAPD guidelines classify patients into “high risk” and “low risk” for caries, using similar criteria to those used in Section 4 of this document, but do not recognise a “moderate risk” category. The authors make the following recommendations:

- Bitewing radiographs should be taken only if they are considered necessary for adequate treatment.
- For both caries risk status groups (both high and low risk), 5-year-olds should be considered for bitewing examination.
- For both caries risk status groups, bitewing radiographs should be considered at the age of 8-9 years.

- For both caries risk status groups, bitewing radiographs in the permanent dentition should be considered at the age of 12-14 years (1-2 years after eruption of premolars and second molars).

The recommendations presented in the guidelines are shown in Table 4.1.

While not explicitly stated in the EAPD guidelines, it is assumed that a child attending as a new patient between the ages listed above (eg. at age 6 years) might still be considered for a baseline bitewing examination rather than waiting for the next recommended age point.

Table 4.1: The baseline examinations and intervals to the next bitewing examination in children (adapted from EAPD guidelines)¹

Age of patient at baseline bitewing examination	Interval to next bitewing examination	
	Low caries risk	High caries risk
5 years	3 years	1 year
8-9 years	3-4 years	1 year
12-16 years	2 years	1 year
16 years	3 years	1 year

The EAPD guidelines recommend less frequent bitewing examinations than Section 4. The editors do not feel able to judge definitively between these two approaches and concluded that inclusion of the EAPD recommendations as a valid alternative strategy was appropriate. In terms of the evidence-based approach used by the FGDP(UK), the EAPD guidelines would be judged as grade C (expert opinion).

Readers are recommended to read the full EAPD guideline.¹ In the light of the different strategies for use of radiographs for caries diagnosis in children, dental teams may find this a valuable subject for in-practice discussion.

4A.2 REFERENCE

1. Espelid I, Mejåre I, Weerheijm K. EAPD guidelines for use of radiographs in children. *Eur J Paediatr Dent* 2003;4:40–8. Available at: <http://www.eapd.gr/12A5AECC.en.aspx>. Accessed: July 2013.

5.1 INTRODUCTION

Aradhna Tugnait and Peter Heasman

A large number of research papers have looked at the use of radiographs in periodontal assessment. Much of this work includes the use of radiography to assist and confirm a periodontal diagnosis, to help determine prognosis of the disease and to monitor long-term treatment outcomes. Many studies compare the performance of different radiographic techniques. However, since the majority of these papers are insufficiently directed towards selection criteria, they were not included in this document.

The following points emerged from the papers and guidelines that were reviewed:^{1–30}

- The diagnosis of periodontal diseases depends on a thorough clinical examination supplemented by radiographs, where they may provide additional information that could potentially change patient management or prognosis.^{4R,18R,19}
- Clinicians should always use radiographs taken for caries diagnosis to aid the assessment of the periodontal hard tissues.^{18R}
- There is no clear evidence to support any recommendations regarding the frequency of radiographs taken for periodontal reasons.
- Radiographic assessment of changes in alveolar bone can be improved if sequential intraoral radiographs are placed reproducibly to allow accurate evaluation of changes in the radiographic geometry over time.^{2R,3R,7R}
- There appears to be no evidence on when to take a periapical radiograph to assist in the diagnosis or treatment of periodontal/endodontic lesions.

- The bitewing projection offers both optimal geometry and the fine detail inherent to intraoral radiography. Bitewings have the additional advantage that when they have already been indicated for caries assessment, they offer a means of providing information about bone levels around teeth without the need for an additional radiation dose.⁹
- Full-mouth series of periapical radiographs and panoramic radiographs with supplementary periapicals have been used for periodontal evaluation, with the latter potentially affording a radiation dose advantage over large numbers of intraoral radiographs. The dose from periapical radiographs may, however, be less than that from panoramic and supplementary periapical combinations, if periapicals are restricted to affected teeth.²¹
- When assessing alveolar bone levels, digital radiographs may offer improved measurement accuracy and greater agreement between different observers compared with film radiographs.^{22,23}
- CBCT may offer greater accuracy than conventional two-dimensional intraoral imaging, with superior imaging of bone defects and furcation lesions compared with conventional radiographs.^{24,27} CBCT is not, however, indicated as a routine method of imaging periodontal bone support; evidence-based guidelines for CBCT should be consulted for further guidance on its use.²⁶

5.2 RECOMMENDATIONS

There is insufficient evidence from research into radiographic selection criteria for periodontology to allow for robust, evidence-based recommendations. However, the following are proposed as good practice:

C

CBCT is not indicated as a routine method of imaging periodontal bone support.

C If a patient has generalised pocketing of 4–5 mm (BPE scores of maximum Code 3 in any sextant) and little or no recession, horizontal bitewings are recommended. These may be supplemented by intraoral periapicals for selected anterior teeth, but only if this is likely to change management of the patient.

C Assessment of all teeth and their periodontal support can be achieved by an optimal-quality panoramic radiograph alone, a panoramic radiograph with supplementary periapical radiographs, or a complete series of periapical radiographs. When determining which radiographic technique to use, consideration should be given to the clinical presentation, the required image quality and the relative dose-benefit based on the equipment available.

C A periapical radiograph using a paralleling technique is indicated if a periodontal/endodontic lesion is suspected.

C If a patient has pocketing of 6 mm or more (BPE scores of Code 4), vertical bitewing radiographs are recommended, supplemented by intraoral periapical views using the paralleling technique at sites where alveolar bone image is not included. These may be supplemented by intraoral periapicals for selected anterior teeth, but only if this is likely to change management of the patient.

C

Where CBCT images include the teeth, care should be taken to check for periodontal bone levels when performing a clinical evaluation (report).

It should be emphasised that:

- The use of radiography is secondary to a clinical examination and full mouth periodontal assessment.^{1R,4-6R,18R,19}
- Existing radiographs should be used as far as possible; the extent of bone loss on existing radiographs used with the clinical examination can enable selection of appropriate radiographic views. Previous radiographs may be useful in assessing the rate of disease progression.
- The decision to take further radiographs for the purpose of assessing changes of the periodontal support over time should be on a case-by-case basis, with radiographs secondary to the clinical examination, when they have the potential to change patient management.^{1R,4-6R,18R,19}

5.3 REFERENCES

1. [R] Absi EG. An evidence-based approach to guidelines in dental radiography. *Postgrad Dent* 1996;6:26–34.
2. [R] Benn DK. A review of the reliability of radiographic measurements in estimating alveolar bone changes. *J Clin Periodontol* 1990;17:14–21.
3. [R] Gutteridge DL. The use of radiographic techniques in the diagnosis and management of periodontal diseases. *Dentomaxillofac Radiol* 1995;24:107–13.
4. [R] Hirschmann PN. Radiographic interpretation of chronic periodontitis. *Int Dent J* 1987;37:3–9.
5. [R] Hirschmann PN, Horner K, Rushton VE. Selection criteria for periodontal radiography. *Br Dent J* 1994;176:324–5.
6. [R] Stephens RG, Kogon SL. New US guidelines for prescribing dental radiographs. *J Can Dent Assoc* 1990;56:1019–24.
7. [R] Wennstrom JL. Interpretation of radiographic data on longitudinal loss of periodontal attachment. *J Periodontol* 1990;61:459–61.
8. Walsh TF, Al-Hokail OS, Fosam EB. The relationship of bone loss observed on panoramic radiographs with clinical periodontal screening. *J Clin Periodontol* 1997;24:153–7.
9. Eaton KA, Woodman AJ. Evaluation of a simple periodontal screening technique used in the UK Armed Forces. *Community Dent Oral Epidemiol* 1989;17:17–22.
10. Goodson JM, Haffajee AD, Socransky SS. The relationship between attachment level loss and alveolar bone loss. *J Clin Periodontol* 1984;11:348–59.
11. [R] Jeffcoat MK. Radiographic methods for the detection of progressive alveolar bone loss. *J Periodontol* 1992;63:367–72.
12. Molander B, Ahlqvist M, Grondahl H-G, Hollender L. Agreement between panoramic and intraoral radiography in the assessment of marginal bone height. *Dentomaxillofac Radiol* 1991;20:155–60.
13. Osbourne GE, Hemmings KW. A survey of disease changes observed on dental panoramic tomographs taken of patients attending a periodontal clinic. *Br Dent J* 1992;173:166–8.
14. Rams TE, Listgarten MA, Slots J. Utility of radiographic crestal lamina dura for predicting periodontitis disease activity. *J Clin Periodontol* 1994;21:571–6.
15. Akesson L, Rohlin M, Hakansson H, Nasstrom K. Comparison between panoramic and posterior bitewing radiography in the diagnosis of periodontal bone loss. *J Dent* 1989;17:266–71.
16. Jeffcoat MK, Reddy MS. Progression of probing attachment loss in adult periodontitis. *J Periodontol* 1991;62:185–9.
17. Rohlin M, Akesson L, Hakansson H, Nasstrom K. Comparison between panoramic and periapical radiography in the diagnosis of periodontal bone loss. *Dentomaxillofac Radiol* 1989;18:72–6.
18. [R] Tugnait A, Clerehugh V, Hirschmann PN. The usefulness of radiographs in diagnosis and management of periodontal diseases: a review. *J Dent* 2000;28:219–26.
19. White SC, Heslop EW, Hollender LG, Mosier KM, Ruprecht A, Shrouf MK. Parameters of radiologic care: An official report of the American Academy of Oral and Maxillofacial Radiology. *Oral Surg Oral Med Oral Pathol Oral Radiol Endod* 2001;91:498–511.
20. Molander B, Ahlqvist M, Gröndahl HG. Image quality in panoramic radiography. *Dentomaxillofacial Radiology* 1995;24:17–22.
21. Jenkins WMM, Brocklebank LM, Winning SM, Wylupek M, Donaldson A, Strang RM. A comparison of two radiographic assessment protocols for patients with periodontal disease. *Br Dent J* 2005;198:565–569.

22. Li G, Engstrom PE, Nasstrom K, Lu ZY, Sanderink G, Welander U. Marginal bone levels measured in film and digital radiographs corrected for attenuation and visual response: an in vivo study. *Dentomaxillofac Radiol* 2007;36:7–11.
23. Henriksson CH, Stermer EM, Aass AM, Sandvik L, Moystad A. Comparison of the reproducibility of storage phosphor and film bitewings for assessment of alveolar bone loss. *Acta Odontol Scand* 2008;66:380–384.
24. Vandenberghe B, Jacobs R, Yang J. Detection of periodontal bone loss using digital intraoral and cone beam computed tomography images: an in vitro assessment of bony and/or infrabony defects. *Dentomaxillofac Radiol* 2008;37:252–260.
25. [R] SBU – Swedish Council on Health Technology Assessment. Chronic periodontitis-prevention, diagnosis and treatment. Stockholm: SBU; 2004. Available at: <http://sbu.se/en/Published/Yellow/Chronic-Periodontitis---Prevention-Diagnosis-and-Treatment>. Accessed: September 2013.
26. [R] European Commission. Radiation Protection 172. Cone beam CT for dental and maxillofacial radiology: evidence based guidelines. Luxembourg: European Commission; 2012. Available at: <https://ec.europa.eu/energy/sites/ener/files/documents/172.pdf>. Accessed: January 2018.
27. Walter C, Weiger R, Zitzmann NU. Accuracy of three-dimensional imaging in assessing maxillary molar furcation involvement. *J Clin Periodontol* 2010;37:436–441.

6.1 INTRODUCTION

Shanon Patel and William Saunders

Radiographs are essential during both surgical and non-surgical root canal treatment. A diagnosis, especially involving pain, may be possible without the need for radiographs but it is not possible to undertake the mechanical aspects of treatment adequately without prior knowledge of the root canal anatomy and the configuration and final radiological confirmation that treatment has been completed. In addition, radiographs are an essential aid in the follow-up of treatment to ascertain changes in the periradicular tissues, commensurate with healing.¹

6.2 ENDODONTIC DIAGNOSIS

A careful and complete investigation of the history of the patient's complaint, combined with a thorough clinical examination, may produce sufficient information to formulate a provisional diagnosis. It is often difficult to correlate signs and symptoms with pulpal and periradicular pathology. Therefore, a good-quality pre-operative radiograph will provide additional information to aid diagnosis (Figure 6.1). At least one pre-operative periapical radiograph is necessary for this diagnostic phase. Occasionally a second image from a different vertical or horizontal angle may be required (Figure 6.2). More advanced radiological techniques may be required when the diagnostic yield from conventional radiographs does not give sufficient useful information.²

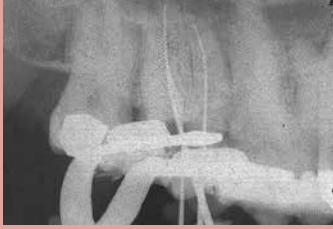

Figure 6.1 This view of an upper second molar show palatal and mesio-buccal roots clearly but the disto-buccal root is obscured.

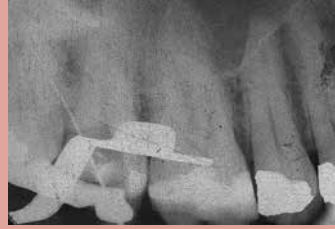

Figure 6.2 A second radiograph of the same tooth. The angulation is different (the same effect may be achieved by altering centering of the beam) and the files in the mesio-buccal and palatal canals have been removed, leaving just one file in what was thought to be the disto-buccal canal but is in fact a distal perforation. The unfortunate result is now clear.

B

A good-quality pre-operative radiograph is essential for diagnosis of endodontic problems.

6.3 ROOT CANAL TREATMENT PLANNING

Assuming that the tooth either has an irreversible pulpitis or periradicular disease of endodontic origin, the pre-operative radiograph will confirm not only the diagnosis, but also reveal possible difficulties likely to be encountered during treatment, and also any other disease associated with the tooth, including periodontal disease and dental caries. Root canal treatment should only be carried out if the tooth is restorable, and has a good long-term prognosis as a functional unit. Whilst there are no true contra-indications to root canal treatment, treatment planning must be carried out holistically, bearing in mind the state of the remaining dentition, the wishes of the patient and the alternative treatment strategies available if the tooth were to be extracted.

One cannot over-emphasise that radiological examination does not provide a definitive diagnosis of the state either of the pulp or periradicular tissues.

6.3.1 Non-surgical root canal treatment

Prior to making decisions regarding root canal treatment, the pre-operative radiograph(s) should be used to ascertain the following information:

- Form and extent of the dental pulp, including both the coronal part and the root canals. Look out for the presence of tertiary dentine coronally, discrete mineralisation such as pulp stones and sclerosis of the root canals.
- The number of roots.
- Approximate length of the tooth and the crown-root ratio.
- Shape of the root, the amount of curvature and the configuration of that curvature. A curve in the apical portion is more difficult to manage than a curve that starts halfway down the root.
- Angulation of the roots.
- Proximity of other anatomical structures, including the maxillary antrum, the inferior dental canal and the mental foramen.
- Amount of supporting bone present.
- Size, shape and position of any periradicular lesion present.
- Evidence and nature of previous root canal treatment, and the type and quality of the coronal restoration present. Marginal defects, including overhangs and recurrent caries may be seen and will influence treatment planning. The presence of pins and posts may also be detected.

If it is not possible to gain sufficient diagnostic power from one periapical radiograph then supplementary views should be considered. This is usually achieved using a second periapical radiograph with a shift of horizontal beam angulation, typically some 10–20 degrees from a mesial or distal direction, to achieve parallax images. This allows separation of roots and may eliminate overlap of anatomical structures, such as the zygomatic arch, with maxillary molars.

6.3.2 Surgical root canal treatment

The same essential information as for non-surgical root canal treatment applies when a surgical approach is being considered. In most cases, orthograde treatment has already been undertaken. Other aspects pertinent to a surgical approach include:

- The likely final length of the root with respect to periodontal bone support
- The proximity of adjacent anatomical structures (eg. the inferior dental nerve and its branches, the maxillary sinus)
- Evidence of root fracture
- Presence of a perforation, either by a post or root canal filling
- Presence of an accessory canal with associated radiolucency
- Presence of extruded obturation material
- The size of the periradicular lesion.

6.4 ROOT CANAL TREATMENT

The aim of non-surgical root canal treatment is to shape and clean the root canal system, removing diseased pulpal tissue and reducing microbial load. The shaping allows more thorough disinfection by irrigation with antimicrobial agents, and facilitates sealing the root canal system with a biocompatible obturation system. Each root canal should be disinfected up to the apical constriction, ie. where the pulp tissue meets the periodontal tissue. The distance from the most coronal reference point to the apical constriction is known as the 'working length'. Obturation material placed at or beyond this level has been shown to be associated with severe inflammation, even in the absence of clinical symptoms.³ Accurate determination of the working length is essential for a successful outcome in endodontic treatment.

Traditionally, this level of instrumentation has been determined radiologically, an image being taken with an instrument in the root canal. However, it is not possible to determine the position of the apical constriction accurately using traditional radiological techniques. This is because the constriction is rarely at the radiological apex of the tooth.

6.4.1 *Electronic apex locators*

Electronic apex locators work on the principle that there is a consistent value of electrical resistance between an instrument in the root canal and an electrode on the oral mucous membrane. The most recent generation of apex locators use impedance measurements instead of resistance to measure the location of a metal instrument in the root canal. These instruments are self-calibrating, using a ratio method. This works on the principle that two electric currents with different sine wave frequencies will have measurable impedances that can be compared. The advantage of these instruments is that they can be used in the presence of electrolyte. An excellent review of these instruments has been provided by Gordon and Chandler,⁴ and they have been shown to be reliable for the determination of working length when used correctly.⁵

Electronic apex locators are not a panacea for determining working length. The presence of large amounts of fluid in the root canal system, metal coronal restorations or a large apical foramen all affect performance adversely.⁶ Although frequent use of a locator improves performance, it may still be considered necessary to confirm the length radiologically.

Most root canal preparation techniques advocate the use of a crown-to-apex approach. The undistorted pre-operative radiograph allows the clinician to measure the length of the tooth, thus allowing the working length to be determined, after which the endodontic files should be marked or fitted with stops to ensure that the apical extent of preparation is not violated. After some initial preparation of the coronal part of the root canal, and use of an electronic apex locator, if available, a radiograph (working length radiograph) should be taken with the endodontic file in place to confirm the working length. If this diagnostic file is more than 3 mm from the proposed working length then the length should be adjusted and a further radiograph taken. In molars it may be necessary to use files of different configuration (such as Flexfiles and Hedstroms) to distinguish root canals that lie in the same plane of the x-ray beam (for example, mesio-buccal and mesio-lingual canals in lower molar teeth). Alternatively, more than one radiograph may be taken to determine the working length for all root canals.

C

Unless there is confidence about working length(s) derived from an electronic apex locator, at least one good-quality radiograph is necessary to confirm working length(s).

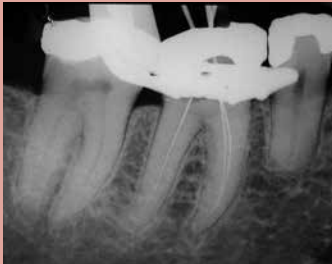

Figure 6.3 Working length radiograph of lower right first molar tooth.

Additional radiographs may be taken during root canal treatment to confirm that working length(s) have been maintained. For example, ‘master’ obturation gutta percha points may be seated within the root canal(s) and a radiograph taken to confirm that they are at the appropriate length (Figure 6.3). In addition, especially if a heated obturation technique is employed and the tooth has an open apex or compromised apical constriction, a

radiograph may be taken after the initial “downpack” of the master cone to ensure that the correct length has been achieved.

C

If there are any doubts about the integrity of the apical constriction or resistance taper of the prepared root canal, a mid-fill radiograph should be taken to confirm the position of the root filling before final compaction is carried out.

In surgical cases, it may be reasonable to take a radiograph of the periradicular tissues prior to suturing to ensure that an adequate root-end filling has been placed and that debridement of the tissues has been completed, especially if there had been a previous overfill or extrusion of material.

6.5 ENDODONTIC FOLLOW-UP

A radiograph should be taken immediately after the root canal treatment has been completed. This applies equally to surgical and non-surgical treatment and provides a baseline reference for subsequent review of the treatment. With molar teeth it may be necessary to take more than one post-operative view. Preferably these radiographs should be processed and reported before the patient leaves the surgery.

An immediate post-operative radiograph will help to provide:

- A rudimentary (two-dimensional) assessment of the quality of the treatment, including length, presence of voids and apical extrusion.
- A baseline for subsequent review.
- An indication of possible complicating factors such as apical 'zipping', transportation of the root canal shape, perforation and areas of potential physical weakness in the tooth as a consequence of over-preparation.
- An indication of potential ways in which the tooth may be restored, including post length, diameter and, if no restoration is present to mask the image, the amount of remaining tooth structure coronally may also be assessed.

C

At least one post-operative radiograph is necessary to assess the success of the obturation, and to act as a baseline for assessment of apical pathology or healing.

The ideal follow-up for assessing healing of periradicular disease remains controversial, as are the criteria for success. Certainly radiological examination alone is insufficient, and must be combined with a careful clinical assessment. The main radiological criterion for judging success is a reduction in the size of a pre-existing periradicular radiolucency. However, research has shown that periapical radiography has a low sensitivity, ie. it is not able to detect all periapical radiolucencies.⁷

The difficulty in diagnosing the presence of disease is complicated further by the histological nature of the radiolucency. Healing may take place by the formation of a fibrous scar rather than new bone. However, it has been shown that the incidence of scar formation is actually quite low, about 2%.⁸

The time required for follow-up continues to be debated, but recent arguments suggest that one year is probably reasonable. If the radiolucency shows evidence of reduction at that time then further review is unnecessary. There is an argument that should there be no change after one year, then further treatment should be considered.⁹ Pragmatically, however, if incomplete healing is seen after one year then the patient should be recalled in a further year when clinical signs can be reviewed and a further radiological examination carried out. It may be that the four-year follow-up period as proposed in guidelines from the European Society of Endodontology¹⁰ may not be necessary.

B

A further follow-up radiograph should be taken at one year after completion of treatment.¹¹

The PAI system is being used more frequently for assessment of success. In this system periradicular radiolucencies are categorised with scores of 1 to 5, score 1 representing periapical health and all other scores representing periradicular disease, with increasing size of the radiolucency (up to 5). The validity of using this classification has been questioned, however, as it was originally developed for maxillary incisors and therefore may not apply to other teeth.¹²

6.6 OTHER ENDODONTIC TREATMENTS

6.6.1 *Vital pulp procedures*

Pulp capping and pulpotomy are performed to retain pulp vitality, especially in teeth with immature apices. A radiograph is necessary at the time of initial treatment to inform treatment planning and provide a baseline for evaluation of the procedure. Radiological review of teeth treated in this way should be undertaken periodically but only combined with a full clinical examination. Radiological success may manifest in the formation of a hard-tissue bridge at the site of the pulp dressing, continued root development and root-end closure. If a tooth treated in this way becomes symptomatic or clinical signs of failure are apparent, then radiographs will be required for further treatment planning.



A baseline radiograph is essential for treatment planning in vital pulp procedures.

6.6.2 *Dental trauma*

Teeth that have been subjected to trauma require careful examination, which includes the use of radiographs. A baseline intraoral radiograph is mandatory following all but minor tooth trauma. In many cases trauma is sustained by children and cooperation is important. Depending on the nature of the injury it may be necessary to take several intraoral radiographs from different angles. Extraoral views, including anterior occlusals, are sometimes useful for luxation injuries. In some instances a small field-of-view cone beam computer tomography (CBCT) scan may be desirable to assess the true nature of luxation injuries and/or cortical plate involvement. Periodic review of injured teeth is essential, including those with horizontal root fractures, where pathological changes at the fracture site can be detected only with the help of radiological examination.

Finally, the American Association of Endodontists has produced a study guide that gives an overview of pertinent literature.¹³

C A baseline radiograph(s) is essential for the management of minor tooth trauma. Follow-up radiographs should be taken at six months after treatment, and then annually until root formation is complete. While expert opinion supports the taking of review radiographs, there is no evidence to support any particular frequency or duration of review.

6.7 CONE BEAM COMPUTED TOMOGRAPHY

The use of CBCT in endodontics is the subject of active research, and there is some evidence that it has a useful role in diagnosis where conventional radiography fails to provide adequate diagnostic information.^{14–21}

Selection criteria for CBCT in dentistry have been published by the European Commission following comprehensive systematic review by the SEDENTEXCT project.²² Criteria for CBCT use in endodontics are included, but the authors of these guidelines acknowledged some important limitations:

- The evidence base remains limited.
- Not all CBCT equipment is the same, particularly with regard to resolution.
- Radiation doses are generally higher than those associated with conventional radiography.
- Significant artefacts are produced by metallic dental restorations that can profoundly reduce image quality.

In an endodontic context, the final bullet point is of particular importance where a tooth, or nearby teeth, contain metal posts or there are adjacent implants. As a result, in the current document, we take a cautious view about the use of CBCT in endodontics, and essentially reproduce the selection criteria derived from the European document.²²

C

CBCT is not indicated as a standard method for demonstration of root canal anatomy.

C

Limited-volume, high-resolution CBCT may be indicated for selected cases where conventional intraoral radiographs provide information on root canal anatomy which is equivocal or inadequate for planning treatment, most probably in multi-rooted teeth.

C

Limited-volume, high-resolution CBCT may be indicated for selected cases when planning surgical endodontic procedures. The decision should be based upon potential complicating factors, such as the proximity of important anatomical structures.

C

Limited-volume, high-resolution CBCT may be indicated in selected cases of suspected, or established, external resorption or internal resorption, where three-dimensional information is likely to alter the management or prognosis of the tooth.

CONTINUED...

C Limited-volume, high-resolution CBCT may be justifiable for selected cases where endodontic treatment is complicated by concurrent factors, such as resorption lesions, combined periodontal/endodontic lesions, suspected perforations, treatment planning prior to periapical microsurgery and atypical root canal anatomy.

In every case being considered for CBCT, careful thought should be given to whether the CBCT equipment is capable of providing the limited volumes (fields of view), and whether high-resolution images required for endodontic imaging can be obtained without an unacceptable increase in radiation dose.

6.8 REFERENCES

1. Forsberg J, Halse A. Radiographic simulation of a periapical lesion comparing the paralleling and the bisecting angle techniques. *Int Endod J* 1994;27:133–8.
2. Patel S. New dimensions in endodontic imaging: part 2. Cone beam computed tomography. *Int Endod J* 2009;42:463–75.
3. Ricucci D, Langeland K. Apical limit of root canal instrumentation and obturation, part 2. A histological study. *Int Endod J* 1998;31:394–409.
4. Gordon MPJ, Chandler NP. Electronic apex locators. *Int Endod J* 2004;37:425–37.
5. Haffner C, Folwaczny M, Galler K, Hickel R. Accuracy of electronic apex locators in comparison to actual length – an in vivo study. *J Dent* 2005;33:619–25.
6. Kang J-A, Kim SK. Accuracies of seven different apex locators under various conditions. *Oral Surg Oral Med Oral Pathol Oral Radiol Endod* 2008;106:e57–e62.
7. Paula-Silva FWG, Wu M-K, Leonardo MR, da Silva LAB, Wesselink PR. Accuracy of periapical radiography and cone beam computed tomography in diagnosing apical periodontitis using histopathological findings as a gold standard. *J Endod* 2009; 35: 1009–12.
8. Love RM, Firth N. Histopathological profile of surgically removed persistent radiolucent lesions of endodontic origin. *Int Endod J* 2009;42:198–202.
9. Wu M-K, Wesselink PR. Timeliness and effectiveness in the surgical management of persistent post-treatment periapical pathosis. *Endodontic Topics* 2005;11:25–31.
10. Quality guidelines for endodontic treatment: consensus report of the European Society of Endodontology. *Int Endod J* 2006;39:921–30.
11. Orstavik D. Time-course and risk analyses of the development and healing of chronic apical periodontitis in man. *Int Endod J* 1996;29:150–5.
12. Wu M-K, Shemesh H, Wesselink PR. Limitations of previously published systematic reviews evaluating the outcome of endodontic treatment. *Int Endod J* 2009;42:656–66.
13. American Association of Endodontists. Endodontic radiology: An online study guide *J Endod* 2008;34(5 suppl):e117–e119.
14. Lofthag-Hansen S, Huuonen S, Gröndahl K, Gröndahl H-G. Limited cone-beam CT and intraoral radiography for the diagnosis of periapical pathology. *Oral Surg Oral Med Oral Pathol Oral Radiol Endod* 2007;103;114–19.
15. Nakata K, Naitoh M, Izumi M, Inamoto K, Arijji E, Nakamura H. Effectiveness of dental computed tomography in diagnostic imaging of periradicular lesion of each root of a multirrooted tooth: A case report. *J Endod* 2006;32:583–7.
16. Rigolone M, Pasqualini D, Bianchi L, Berutti E, Bianchi SD. Vestibular surgical access to the palatine root of the superior first molar: “low-dose cone-beam” CT analysis of the pathway and its anatomic variations. *J Endod* 2003;29,773–5.
17. Cotton TP, Geisler TM, Holden DT, Schwartz SA, Schindler WG. Endodontic applications of cone-beam volumetric tomography. *J Endod* 2007;29:1121–1132.
18. Patel S, Dawood A, Whites E, Pitt Ford T. The potential applications of cone beam computed tomography in the management of endodontic problems. *Int Endod J* 2007;40:818–830.
19. Patel S, Dawood A, Whites E, Pitt Ford T. New dimensions in endodontic imaging: part 1. Conventional and alternative radiographic systems. *Int Endod J* 2009;42:447–462.
20. Patel S, Dawood A, Wilson R, Horner K, Mannocci F. The detection and management of root resorption lesions using intraoral radiography and cone beam computed tomography – an in vivo investigation. *Int Endod J* 2009;42:831–38

21. Patel S, Horner K . Editorial: The use of cone beam computed tomography in endodontics. *Int Endod J* 2009;42:755–6.
22. [R] European Commission. Radiation Protection 172. Cone beam CT for dental and maxillofacial radiology: evidence based guidelines. Luxembourg: European Commission; 2012. Available at: <https://ec.europa.eu/energy/sites/ener/files/documents/172.pdf> . Accessed: January 2018.

7.1 INTRODUCTION

Crawford Gray and Richard Palmer

The literature on radiology in implant dentistry was reviewed by a MEDLINE and PubMed search, examination of review papers,¹⁻⁴ consensus documents,⁵⁻⁷ a review of relevant sections of two textbooks on implant dentistry,^{8,9} and two textbooks of oral radiology.^{10,11} From these, it was clear that there is considerable knowledge of the value of the various imaging methods used in implant dentistry. However, there was some disagreement on the selection criteria in individual clinical situations, and little information on the frequency and duration of follow-up radiographs after treatment completion. Overall, it can be concluded that, at present, there is a limited evidence base on which to formulate guidelines for the use of radiographs in implant dentistry.

In implant dentistry, radiography plays a crucial role in treatment planning (see Table 7.1), the assessment of available bone, and reviewing long-term maintenance. Successful implant placement is facilitated by the availability of adequate information about the quantity and quality of bone at the proposed implant site in relation to the position and design of the planned prosthesis. Radiology is also needed to assess existing natural teeth and healing of extraction sockets where implant placement is planned. Routine radiology does not allow visualisation of the process of osseointegration, ie. the attachment of bone to an implant surface. However, the presence of peri-implant radiolucency may suggest fibrous tissue encapsulation/epithelial downgrowth indicative of implant failure.³ Baseline radiographic examination is usually recommended at the completion of the prosthodontic phase of treatment to assess marginal bone levels for future reference and to check on the correct connection of the implant components. Further paralleled images should be made at appropriate post-treatment intervals to monitor peri-implant bone levels.

Table 7.1: Radiology for treatment planning in implant dentistry

SINGLE IMPLANT	
Anterior maxilla	Periapical radiograph. If cross-sectional information is needed, possibly use limited-volume CBCT.
Premolar maxilla	Periapical and/or panoramic radiograph. If cross-sectional information is needed, possibly use limited-volume CBCT.
Molar maxilla	Periapical and/or panoramic radiograph. If cross-sectional information is needed, possibly use limited-volume CBCT, especially to visualise the antral floor.
Anterior mandible	Periapical radiograph. If cross-sectional information is needed, possibly use limited-volume CBCT to show lingual fossae.
Post-foaminal mandible	Periapical and/or panoramic radiograph. To show three-dimensional position of the inferior dental canal and to investigate concavities of lingual/submandibular fossae, possibly use limited-volume CBCT.
MULTIPLE IMPLANTS	
Multiple exposures using the above guidance can become unwieldy and carry significant radiation exposure. A good panoramic radiograph with magnification markers can often give excellent information. Where cross-sectional information is needed, CT, limited or full-volume CBCT should be used, if the exposure is likely to improve the outcome for patient and surgeon. MRI could be considered as it entails no exposure to ionising radiation.	
IF REQUIRED DURING SURGERY	
Periapical radiographs should be used, with radiographic measurement markers. For ease of use during surgery, the use of a digital system should be considered.	
POST-OPERATIVE	
Periapical and/or panoramic radiographs may be used.	
GENERAL GUIDANCE AND POST-TREATMENT REVIEW	
<p>Periapical and panoramic radiographs give good two-dimensional information, but the surgeon must be aware of potential magnification and patient positioning errors. The use of sectional imaging is appropriate in complex and anatomically challenging cases, but the surgeon should be aware of the need to reduce the dose by using CBCT and MRI rather than conventional CT. In all cases, the technique employed should justify the radiation dose.</p> <p>Post-operative review protocols appear to be the subjective opinion of authors. A radiograph at completion of the restoration and 12 months later may be considered essential in gaining baseline data and assessment of any changes in bone levels due to factors such as remodelling, function or inflammation. An ongoing review interval of one, three, or up to five years is suggested, to verify stability of bone levels or to detect progressive bone loss. A careful clinical examination should be able to indicate a stable situation, but it is advisable to obtain radiographic evidence of bone levels if signs are present that may suggest deterioration, eg. increased probing depth, bleeding, exudate, mobility.</p>	

Table 7.2: Recommended two-dimensional imaging for implant dentistry

	Intraoral radiography	Panoramic radiography
Maxilla		
Single tooth	X	
Dentate	X	X
Edentulous	X (single site)	X
Mandible		
Single tooth	X	
Dentate	X	X
Edentulous	X (single site)	X

Sectional imaging is commonly used in complex cases, and sophisticated three-dimensional radiological techniques may be employed to formulate treatment protocols or to construct guides for surgical implant placement and prefabrication of prostheses.¹²

The choice of radiographic technique used in implant dentistry is further complicated by a number of factors, including the experience of the surgeon. While an experienced practitioner may have adequate information from a site using two-dimensional imaging, a less experienced practitioner may feel more confident having the additional information gained from a three-dimensional technique. As with any radiological investigation, dose limitation is a paramount factor in the choice of the imaging modality.

7.2 REVIEW OF RADIOLOGICAL TECHNIQUES

Of the many radiological techniques available, the following are relevant to implant dentistry.

7.2.1 Periapical radiography

Periapical radiographs are commonly used in dental implant treatment planning. Apart from being the most appropriate method of assessing the remaining teeth and edentulous areas for pathology and the position of anatomical structures, periapical radiographs are often used to assess the bone height available.

The main limitation in the use of periapical radiographs is that the image is only two-dimensional, with no information of the third dimension (bone width or buccolingual position of the neurovascular bundle). They may be the radiograph of choice for single tooth replacement in uncomplicated sites, and are particularly useful to assess spaces that may appear narrow or where root convergence is suspected. Following surgery, they may be used to assess whether placement has been satisfactory in terms of spacing, angulation and depth. In cases where anatomical structures might limit safe implant placement, a stepwise approach may be adopted using a radiopaque graduated depth gauge, placed to a known depth in the osteotomy site. A periapical radiograph aligned using a paralleling technique is then exposed, allowing the operator to accurately measure distances to vital structures such as the inferior dental nerve. For more difficult cases pre-operative sectional imaging should be considered. Periapical radiographs may also be used to monitor the peri-implant hard tissues at post placement intervals (see Tables 7.1 and 7.2).

It is best practice to use image receptor holders and the paralleling technique in periapical radiography. All intraoral radiographs are magnified to a degree dependent upon the focus, object and image receptor geometry. With a good paralleling technique and avoidance of distorting the film/sensor this can be kept to a minimum and should not unduly affect planning of implant length/diameter. A reference object of known size, such as a metal ball bearing, may be imaged in the same plane as the alveolus, and accurate distances can be calculated. The markers need to be placed close to the site being proposed for implant placement, and may be incorporated within a stent or denture. Even with paralleling, the accuracy of radiographs may be within a ± 2.5 mm range.¹³ Imaging can be a problem when dealing with a resorbed edentulous alveolus, where the image receptor holder may dig into the palate or lingual sulcus. The use of cotton wool rolls between

the edentulous ridge and bite block may help; nevertheless, in some cases, periapical images may show little more than the superficial few millimetres of bone. This limitation may lead the clinician to use other specialised techniques.

It should be noted that many of the direct digital periapical radiographic sensors are bulky, and although they may give virtually instantaneous images (with reduced radiation dose) it is often impossible to achieve a good paralleling technique. Although they do not offer instant imaging, digital radiography using phosphor plates allows for simpler placement of the image receptor.

In all dental periapical radiography, rectangular collimation using a suitable paralleling technique should be employed.

7.2.2 Occlusal radiography

True occlusal radiographs, while having no role in maxillary implant planning, may rarely be useful in mandibular implant planning. The image may help to demonstrate the course of the inferior alveolar canal; however, the images only show the maximal buccolingual bone width, giving no indication of the cross-sectional jaw shape. As with periapical radiographs, magnification of images should be considered.

7.2.3 Panoramic radiography

Simple panoramic images provide general information about bone height, the position of anatomical structures such as the inferior dental canal, mental foramen and maxillary antral floor, and a limited indication of bone quality. One of the most critical areas is the visualisation of the inferior dental canal, mental foramen and the complex morphology of the canal to avoid damage to the nerve during implant placement. Panoramic radiographs may be considered adequate for implants placed in the posterior mandible, providing a minimum 2 mm or preferably 4 mm safety margin is adopted,¹⁴ and bone width is judged to be clinically sufficient (see Tables 7.1 and 7.2).

It is extremely important to remember that panoramic images are magnified by up to 30%, and that such magnification may vary significantly at different locations within

the same radiograph, depending upon the equipment used. It is essential that the patient is positioned accurately for panoramic radiography as dimensional distortion may occur depending on the position within the focal trough and angulation of the jaw. These positioning variations lead to changes in magnification¹⁵ along with distortion, which may vary considerably at differing points along the dental arch. As far as this is concerned, it is fortunate that vertical measurements are affected much less than those in the horizontal plane. As a guide, during radiography it may be useful to employ reference objects, such as ball bearings in a baseplate in the line of the arch, as close to the proposed implant site as possible. At the early stage of edentulous patient assessment, leaving acrylic dentures in place will allow more accurate positioning of the patient.

7.2.4 Lateral cephalometric radiography

This may be of some use in the anterior jaw regions because it gives a cross-sectional image of the mid-line of the maxilla and mandible. The view gives some information on the trabecular density of the bone and the potential inclination of any proposed implants in the region concerned; however, it is of very little use elsewhere in either jaw because right and left sides are superimposed. Care must be taken with patient positioning in relation to the beam, in order to reduce positioning errors.¹⁶ Practitioners without access to a cephalographic facility might wish to consider a transsymphyseal view, which would give comparable information of the mandible to the lateral cephalometric view.¹⁷

7.2.5 Conventional cross-sectional tomography

This technique requires equipment in which there is controlled movement of the x-ray source and receptor around a fixed patient. There are two main types available. The first, using modified panoramic equipment, has additional software to allow cross-sectional images to be produced. This is relatively inexpensive but can be time-consuming and is a demanding technique for the operator to perform well; furthermore, variable magnification errors occur, similar to those that can be produced during panoramic radiography. The second type is a more sophisticated machine that produces cross-sectional images of known magnification perpendicular to the line of the dental arches.

It should be noted that using such equipment for multiple sites may result in a substantial exposure to radiation.¹⁸ When employing tomography, it is recommended that an imaging stent, containing radiopaque reference markers, is used.

7.2.6 X-ray computed tomography (CT)

CT scanning is an imaging modality that allows the clinician to acquire sectional detail of the mandible and/or maxilla in a single procedure. A series of axial slices are captured and processed by computer to construct cross-sectional images of the jaws, often using dedicated dental software. The images may be made life-size, are normally accurate within a range of ± 1 mm, and can be reformatted to produce images in other planes. An estimate of bone density in Hounsfield Units (HU) can be made from CT scans, and sophisticated software may be used to produce interactive implant planning tools (see Table 7.1 and Table 7.3 overleaf).

It should be noted that identification of the inferior dental canal in the lower molar region is not always possible on CT sectional images.¹⁹ As the radiation exposure from CT may be considerable, the use of dose reduction techniques and limitation of the target field is imperative. Due to the high radiation dose, it is not justifiable to use CT for repeated examinations in implant dentistry.

During CT imaging, metallic objects – such as amalgam restorations – may cause significant artefacts, which can lead to difficulties in interpretation. While scanning times are fairly quick, any movement of the patient between successive axial scans will lead to motion artefacts with possible inaccuracies in shape and size of the image.

7.2.7 Cone beam computed tomography

The use of cone beam computed tomography (CBCT) has progressed rapidly in the last few years and offers a much reduced exposure to radiation, the production of images of similar quality to medical CT and a much lower capital investment in the purchase of the equipment. For radiation-based sectional imaging, CBCT is becoming established as the modality of choice. CBCT is established in many dental practices for implant planning and in combination with stereolithic

Table 7.3: Recommended x-ray cross-sectional imaging modalities for implant dentistry

	Limited-volume cone beam CT	Full-volume cone beam CT	X-ray CT
MAXILLA – Single tooth			
a. Incisive canal	X		
b. Shape of maxillary sinus	X		
c. Clinical doubt on shape of alveolar ridge	X		
MAXILLA – Dentate			
a. Shape of maxillary sinus	X (for limited region of interest)	X (for multiple regions)	X (for multiple regions and having no access to CBCT)
b. Clinical doubt on shape of alveolar ridge	X (for limited region of interest)	X (for multiple regions)	X (for multiple regions and having no access to CBCT)
MAXILLA – Edentulous			
a. Shape of maxillary sinus		X	X (for multiple regions and having no access to CBCT)
b. Clinical doubt on shape of alveolar ridge		X	X (for multiple regions and having no access to CBCT)
MANDIBLE – Single tooth			
a. Clinical doubt on position of mandibular canal or mental foramen	X		
b. Clinical doubt on shape of alveolar ridge	X		

CONTINUED...

Table 7.3 (continued)

	Limited-volume cone beam CT	Full-volume cone beam CT	X-ray CT
MANDIBLE – Dentate			
a. Clinical doubt on position of mandibular canal or mental foramen	X (for limited region of interest)	X (for multiple regions)	X (for multiple regions and having no access to CBCT)
b. Clinical doubt on shape of alveolar ridge	X (for limited region of interest)	X (for multiple regions)	X (for multiple regions and having no access to CBCT)
MANDIBLE – Edentulous			
a. Severe resorption		X	X (for multiple regions and having no access to CBCT)
b. Clinical doubt on shape of alveolar ridge		X	X (for multiple regions and having no access to CBCT)
c. Clinical doubt on position of mandibular canal if posterior implants are to be placed		X	X (for multiple regions and having no access to CBCT)

surgical guides and prefabricated prostheses in a similar manner to established medical CT systems.²⁰

As the name suggests, CBCT builds up a three-dimensional image from a dataset acquired from a cone beam projection.²¹ Radiation exposure from CBCT is almost always less than from conventional CT and in some cases may be 2–3 times the exposure of a panoramic radiograph, but this may vary considerably in different machines.²² Dental CBCT units are usually smaller than standard CT scanners, and the jaws are imaged in a single scan rotation. The machines use either an image intensifier or a flat panel detector for image capture. CBCT images may either be viewed on the workstation, or be exported to various post-processing software

packages to allow interactive implant planning. Most manufacturers have an export function, allowing the data to be sent out to referring dentists with a simple imaging program.

There are two basic types of CBCT scanners: limited and full-volume CBCT.

Limited-volume CBCT images a small volume (typically a few centimetres in diameter) which would be of use for single or adjacent implant sites. While many potential implant sites may be imaged by limited-volume CBCT, the cumulative dose effect should be appreciated when multiple sites are imaged. For more complex cases, where multiple implants are being placed in different regions of the mouth, a full-volume acquisition would be preferable. Many full-volume scanners have the ability to acquire limited-volume images, reducing their radiation dose further. As full-volume CBCT images often include the skull base, these scans need to be viewed by a suitably qualified radiologist to exclude the presence of any unexpected lesions. While the dimensional accuracy of CBCT is comparable with CT,²³ other investigations such as measurement of bone density in Hounsfield Units are not reproducible²⁴ (see Table 7.1 and 7.3).

As with all radiological examinations, a justification for the exposure must be made by the operator, and the exposure should be reduced by limiting the field of view and maximising other exposure-reducing factors, while still producing a diagnostic image.^{10,11}

Referring dentists should also be aware of their responsibilities to radiation exposure and full training should be given to staff operating CBCT machines to ensure that they are capable of initiating dose reduction strategies.

7.2.8 Magnetic resonance imaging (MRI)

MRI is a sectional tomographic imaging modality that does not use ionising radiation, but it is not widely used in implant dentistry. Direct cross-sectional views of the jaws may be made in any plane and with a high degree of accuracy,^{2,25} comparable to those obtained with CT²⁶ (see Table 7.1). The anatomy is best shown using T1-weighted sequences. Normal restorative materials are unlikely to produce significant

artefacts on MRI scans. However, ferromagnetic objects, such as orthodontic brackets and temporary crown posts, can cause severe distortion. As image acquisition times may be longer than for other modalities, a good fast spin echo sequence design is recommended.

7.3 CHOICE OF TECHNIQUES

An initial radiographic examination of a proposed implant site, using periapical films or panoramic radiographs, is essential to exclude the presence of any retained root or other abnormality which might require preliminary surgery or contra-indicate implant placement. They must be used in the light of each patient's individual needs. CT is associated with considerable dose implications that need to be clinically justified. Cross-sectional tomography will give a lower radiation exposure when used in single sites, while MRI creates no exposure to ionising radiation. Finally, the choice of imaging modality may be limited by the availability of facilities and the costs involved (see Table 7.1).

7.4 REFERENCES

1. Frederiksen NL. Diagnostic imaging in dental implantology. *Oral Surg Oral Med Oral Pathol Oral Endod* 1995;80:540–54.
2. Gray CF, Redpath TW, Smith FW, Staff RT. Advanced imaging: magnetic resonance imaging in implant dentistry. *Clin Oral Implants Res* 2003;14:18–27.
3. Albrektsson T, Zarb GA, Worthington P, Eriksson AR. The long-term efficacy of currently used dental implants: a review and proposed criteria for success. *Int J Oral Maxillofac Implants* 1986;1:11–25.
4. Harris D et al. EAO guidelines for the use of diagnostic imaging in implant dentistry. A consensus workshop organized by the European Association for Osseointegration in Trinity College Dublin. *Clin Oral Implants Res* 2002;13:566–70.
5. Harris D et al. EAO guidelines for the use of diagnostic imaging in implant dentistry 2011. A consensus workshop organized by the European Association for Osseointegration at the Medical University of Warsaw. *Clin Oral Implants Res* 2012;23:1243-53.
6. Horner K, Islam M, Flygare L, Tsiklakis K, Whaites E. Basic principles for use of dental cone beam computed tomography: consensus guidelines of the European Academy of Dental and Maxillofacial Radiology. *Dentomaxillofacial Radiology*. 2009;38: 187–95.
7. [R] European Commission. Radiation Protection 172. Cone beam CT for dental and maxillofacial radiology: evidence based guidelines. Luxembourg: European Commission; 2012. Available at: <https://ec.europa.eu/energy/sites/ener/files/documents/172.pdf> . Accessed: January 2018.
8. Lekholm U, Zarb GA. Patient selection and preparation. In: Branemark P-I, Zarb G, Albrektsson T, editors. *Tissue integrated prostheses. osseointegration in clinical dentistry*. Berlin: Quintessence; 1985.
9. Palmer RM, Howe LC, Palmer PJ. *A clinical guide to implants in dentistry*, 2nd ed. London: British Dental Association; 2008.
10. Gratt BM, Shetty V. Implant radiology. In: Goaz PW, White SC, editors. *Oral Radiology. Principles and Interpretation*. St Louis: Mosby; 1994.
11. Whaites E. *Essentials of dental radiography and radiology*, 4th ed. Edinburgh: Churchill Livingstone; 2007.
12. Guerrero ME, Jacobs R, Loubele M, Schutyser F, Suetens P, van Steenberghe D. State of the art on cone beam CT imaging for preoperative planning of implant placement. *Clin Oral Investig* 2006;10:1–7.
13. Sherrard JF, Roussouw PE, Benson BW, Carrillo R, Buschang PH. Accuracy and reliability of tooth and root lengths measured on cone-beam computed tomographs. *Am J Orthod Dentofacial Orthop* 2010;137(4 suppl):S100-8.
14. Vasquez L, Saulacic N, Belsler U, Bernard JP. Efficacy of panoramic radiographs in the preoperative planning of posterior mandibular implants: a prospective clinical study of 1527 consecutively treated patients. *Clin Oral Implants Res* 2008;19:81–5.
15. Bolin A, Eliasson, von Beetzen M, Jansson L. Radiographic examination of mandibular posterior implant sites: correlation between panoramic and tomographic determinations. *Clin Oral Implants* 1996;7:354–359.
16. Verhoeven JW, Cune SC. Oblique lateral cephalometric radiographs of the mandible in implantology: usefulness and accuracy of the technique in height measurements of mandibular bone in vivo. *Clin Oral Implants* 2000;11:39–43.
17. Shelley A, Horner K. A transsymphyseal x-ray projection to assess the anterior edentulous mandible prior to implant placement. *Dental Update* 2008;35:689–694.

18. Dula K, Mini R, Lambrecht JT, van der Stelt PF, Schneeberger P, Clemens G, et al. Hypothetical mortality risk associated with spiral tomography of the maxilla and mandible prior to endosseous implant treatment. *Eur J Oral Sci* 1997;105:123–9.
19. Imamura H, Sato H, Matsuura T, Ishikawa M, Zeze R. A comparative study of computed tomography and magnetic resonance imaging for the detection of mandibular canals and cross sectional areas in diagnosis prior to dental implant treatment. *Clin Implant Dent Relat Res* 2004;6:75–81.
20. Verduyssen M, Jacobs R, Van Assche N, van Steenberghe D. The use of CT scan based planning for oral rehabilitation by means of implants and its transfer to the surgical field: a critical review on accuracy. *J Oral Rehab* 2008;35:454–74.
21. Arai Y, Tammissalo E, Iwai K, Hashimoto K, Shinoda K. Development of a compact computed tomographic apparatus for dental use. *Dentomaxillofac Radiol* 1999 28: 245–248.
22. Ludlow JB. Comparative dosimetry of dental CBCT devices and 64-slice CT for oral and maxillofacial radiology. *Oral Surg Oral Med Oral Pathol Oral Radiol Endod* 2008;106:106–14
23. Hashimoto K, Kawashima S, Araki M, Sawada K, Akiyama Y. Comparison of image performance between cone-beam computed tomography for dental use and four-row multidetector helical CT. *J Oral Sci* 2006;48:27–34
24. Bryant A, Drage N, Richmond S. Study of the scan uniformity from an i-CAT cone beam computed tomography dental imaging system. *Dentomaxillofac Radiol* 2008;37:365–374.
25. Nasel CJ, Pretterklieber M, Gahleitner A, Czerny C, Breitenseher M, Imhof H. Osteometry of the mandible performed using dental MR imaging. *Am J Neuroradiol*. 1999;20:1221–7.
26. Aguiar MF, Marques AP, Carvalho AC, Cavalcanti MG. Accuracy of magnetic resonance imaging compared with computed tomography for implant planning. *Clin Oral Implant Res* 2008;19:362–5.

8.1 INTRODUCTION

Ann Shearer and Andrew Shelley

This section draws on the evidence presented in other sections in formulating an imaging strategy for the adult patient. For details of the evidence behind these recommendations, the reader should refer to the appropriate sections.

The prescription of radiographs should always be based on a thorough history and oral examination. The routine use of x-rays based on a generalised approach rather than individual prescription is unacceptable.

In order to plan treatment for the adult patient, the practitioner will require information. In the dentate patient, this may include:

- Presence of caries.
- Condition of existing restorations.
- Alveolar bone levels.
- Root morphology.
- Morphology of pulp chamber.
- Signs of periapical pathology.
- Position of unerupted teeth or retained roots.
- Other pathology of the jaws.

Additionally, where dental implants are planned, this may include:

- Form and quality of the edentulous ridge and underlying bone.
- Boundaries of relevant anatomical features.

Notwithstanding, radiographic examination should only be carried out where the results will potentially affect patient management. Where management is known in advance to be the same with or without a radiographic examination, such examination cannot be justified.

8.2 THE NEW ADULT PATIENT

A flow diagram incorporating radiographic selection criteria, suitable for the adult new patient, is shown in Figure 8.1. This flow diagram is a guide and clinical judgement should be used. For example, a patient with few remaining teeth and severe alveolar bone loss may not need any radiographs in order to plan treatment.

8.2.1 *Panoramic radiography*

A panoramic view may sometimes be useful in the presence of extensive gross oral disease and concurrent oral surgical or orthodontic problems. The limitations of the panoramic view should be taken into consideration, and supplementary intraoral views may be necessary to show appropriate detail (Section 2.2).

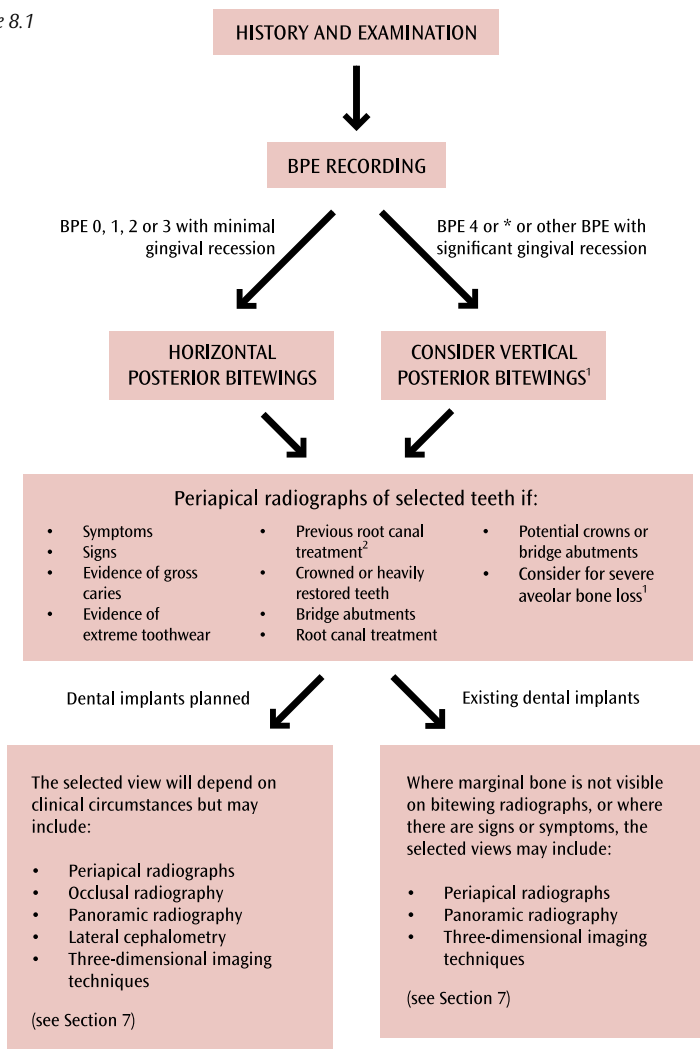
There are other indications for panoramic radiography; for example, in some oral surgical situations. These are discussed in Section 2.2. Nonetheless, it is stressed that routine screening with panoramic radiography cannot be justified.

8.2.2 *Cone beam computed tomography (CBCT)*

CBCT technology holds promise for the future of dental imaging. The presently available evidence does not support the routine prescription of CBCT imaging in the diagnosis of dental caries, periodontal disease or in endodontic therapy. In particular, caution is required because beam-hardening artefacts on CBCT from metallic restorations will produce artefactual “caries”. Nevertheless, where CBCT images are already available, care should be taken to check for dental caries, alveolar bone levels and periapical disease.

The use of CBCT in endodontics is the subject of active research, and there is some evidence that it has a useful role in diagnosis where conventional radiography fails to provide adequate diagnostic information (see Section 6.7).

Figure 8.1



1. A judgement should be made of the fewest radiographs required to appropriately demonstrate alveolar bone levels and dental caries. This will be a combination of periapical radiographs, horizontal bitewing radiographs and vertical bitewing radiographs. For the detection of posterior approximal caries, a horizontal or vertical bitewing view should be selected because of the optimal geometry offered by bitewing radiography.
2. Depending on time since root canal treatment was completed and availability of previous radiographs.

Where dental implants are planned, CBCT may be appropriate to visualise available bone volume and adjacent anatomical structures¹ (see Section 7).

C

The presently available evidence does not support the routine prescription of CBCT imaging in the diagnosis of dental caries or periodontal disease, or in endodontic therapy.

8.3 SPECIFIC CLINICAL SITUATIONS

8.3.1 *Extraction of teeth*

Where there are existing radiographs, these should be referred to before extraction of teeth. There is no convincing evidence to support the need for routine radiography prior to extractions in adults. Nevertheless, in some selected cases, a pre-extraction radiograph would be judicious.²

These are:

- A history of previous difficult extractions.
- A clinical suspicion of unusual anatomy.
- A medical history placing the patient at special risk if complications were encountered.
- Prior to orthodontic extractions.
- Extraction of teeth or roots that are impacted, buried or likely to have a close relationship to important anatomical structures.

With the exception of third molars, the appropriate radiograph will normally be a periapical view.

C

There is no convincing evidence to support the need for routine radiography prior to extractions in adults.

8.3.2 Heavily restored teeth

Apical periodontitis can develop in heavily restored, crowned or endodontically treated teeth. For example, in a meta-analysis of 28,881 endodontically treated teeth, Pak *et al* found that 36% had periapical radiolucencies.³ Similarly, Saunders and Saunders found that 19% of all non-root-filled, crowned teeth had evidence of periapical periodontitis.⁴ Brooks and Cho found a significant association between the depth of restorations and periapical pathology.⁵

Apical periodontitis can arise without any symptoms. This raises the question of which teeth should be radiographed to screen for the presence of periapical periodontitis and how often. Kirkevang and Wenzel carried out a study of 1199 adults to identify the best predictors to assist the decision whether to take additional radiographic images to detect apical periodontitis.⁶ The strongest predictor was the presence of root fillings. Another important predictor was the presence of three or more inadequate coronal restorations in the mouth. Nevertheless, apical periodontitis can also develop in teeth with well-placed restorations.

Until further evidence emerges, it seems prudent, for the new adult patient, to select periapical views for all teeth which are root-filled, or heavily restored, with either direct or indirect restorations. Where direct restorations have been placed, the definition of “heavily restored” must remain a matter of judgement. The frequency of follow-up radiographs of such teeth will also be a judgement based on clinical circumstances, signs and symptoms.

C

It is prudent, for the new adult patient, to select periapical views for all teeth which are root-filled, or heavily restored, with either direct or indirect restorations.

8.3.3 Toothwear

There is a concern that aggressive toothwear may overwhelm the reactive processes of the dental pulp, leading to necrosis and periapical periodontitis. This may suggest that new adult patients with severe toothwear should be screened using periapical radiography. Nevertheless, Rees *et al* found that 99% of teeth with severe toothwear did not have apical pathology.⁷ The authors suggest that the slow process of toothwear allows the defence mechanisms of the pulp to counteract the effects of wear, and they question the necessity of taking routine radiographs of teeth with wear into dentine. It is therefore recommended that only those teeth with extreme toothwear are investigated further with periapical radiography, unless worn teeth fall into one of the other categories in Figure 8.1 such as presence of symptoms or signs. Periodic follow-up radiographs of teeth with extreme toothwear are unnecessary except in the presence of signs or symptoms.

C

For the new adult patient, only those teeth with extreme toothwear should be further investigated with periapical radiography.

8.3.4 Radiographs for the estimation of endodontic working length

Reliable electronic apex locators have replaced the need for radiographs to determine working length in many cases. Where there is doubt about the reliability of the electronic measurement, then a radiograph should be taken with an endodontic file in place to make an assessment of the working length. A check radiograph of a master gutta percha point, seated in the root canal, may also be used (Section 6.4).

C

Where there is doubt about the reliability of electronic measurement, then a radiograph should be taken with an endodontic file in place to make an assessment of the working length.

8.4 LONG-TERM REVIEW AND MAINTENANCE

8.4.1 *Periodontal*

The decision to take further radiographs for the purpose of assessing changes in periodontal support over time should be on a case-by-case basis. Radiographs should be secondary to the clinical examination and should be taken when they have the potential to change patient management (see Section 5).

8.4.2 *Caries*

The prescription of periodic bitewing radiography should be based on a caries risk assessment. For those adults designated as being at high caries risk, bitewing radiographs should be taken every six months and, for those at moderate risk, annually until no new lesions or active lesions are apparent and the patient has entered another risk category. For those at low risk, bitewing radiographs should be taken at approximately two-year intervals. More extended radiographic recall intervals may be employed if there is explicit evidence of continuing low caries risk.

In the absence of clinical indications to re-assess alveolar bone levels, horizontal rather than vertical bitewing radiographs will be the view of choice.

Consideration should be given to alternative methods of caries diagnosis, such as fiberoptic transillumination, described in Section 4.5.3. Nevertheless, most are presently regarded only as adjunctive. Some, such as laser fluorescence, have been shown to have poor specificity. Until further evidence emerges, these should not replace radiographic methods.

8.4.3 Endodontic follow-up radiographs

A radiograph (or radiographs) should be taken immediately following obturation. A one-year follow-up is recommended to assess healing even for asymptomatic teeth. If there is incomplete healing, a further annual follow-up is recommended until healing occurs. Large periapical radiolucencies should be monitored more frequently. Teeth that remain symptomatic may require additional radiographic review to assess the treatment options (see Section 6).

8.4.4 Dental implants

The purpose of routine radiography following dental implant placement is to monitor marginal bone levels and the success of osseointegration. For follow-up of single dental implants, periapical views should normally be selected. In cases of multiple dental implants, multiple periapical views or a panoramic view may be appropriate. A judgement should be made based on the detail required and the dose implications. Where marginal bone levels of posterior implants are visible on periodic bitewing radiography, and there are no other concerns, this may reduce the need for further views.

Radiography immediately after implant placement is only recommended where there is doubt about the position of the implant in relation to adjacent anatomical structures, or where there are unexpected complications during surgery which warrant radiographic examination. In the immediate post-surgical period, a radiograph may be justified if there are unexpected signs or symptoms.

A baseline radiographic record is required so that this can be compared with future views. It is recommended that this be taken at the time of completion of the prosthodontic phase of treatment. Views are recommended after a further 12 months. Radiographs may then be taken at intervals of up to five years.

Additional or more frequent radiographic examination may be required if there are signs or symptoms, or if there is marginal bone loss in excess of what is expected. Only in rare cases, where there are signs or symptoms, will a three-dimensional view will be appropriate (see Section 7).

8.5 REFERENCES

1. Harris D et al. EAO guidelines for the use of diagnostic imaging in implant dentistry 2011. A consensus workshop organized by the European Association for Osseointegration at the Medical University of Warsaw. *Clin Oral Implants Res* 2012;23:1243-53.
2. Dental Protection. The whole tooth – and nothing but the tooth! *Dental News* 1999;20:7-8.
3. Pak JG, Fayazi S, White SN. Prevalence of periapical radiolucency and root canal treatment: A systematic review of cross-sectional studies. *Journal of Endodontics* 2012;38:1170–1176.
4. Saunders WP, Saunders EM. Prevalence of periradicular periodontitis associated with crowned teeth in an adult Scottish subpopulation. *Br Dent J* 1998; 185:137–140.
5. Brooks SL, Cho SY. Validation of a specific selection criterion for dental periapical radiography. *Oral Surg Oral Med Oral Pathol* 1993;75:383–386.
6. Kirkevang LL, Wenzel A. Risk indicators for apical periodontitis. *Community Dent Oral Epidemiol* 2003;31:59–67.
7. Rees JS, Thomas M, Naik P. A prospective study of the prevalence of periapical pathology in severely worn teeth. *Dental Update* 2011;38:24–26, 28–29.

9.1 DO'S AND DON'TS

Ken Eaton and Andy Toy

9.1.1 Do

BEFORE TAKING A RADIOGRAPH

In all cases:

- Complete a thorough history and examination, including the tooth-bearing areas.
- Seek originals or copies of radiographs taken elsewhere if they are relevant. All NHS hospitals now store all patient images (including radiographs) in the Picture Archiving and Communications System (PACS) which enables them to transmit radiographs electronically to other NHS providers. This source should therefore be considered.

FOR CARIES DIAGNOSIS

- Carry out a thorough clinical examination of clean, dry teeth prior to taking a radiograph (this may include transillumination, flossing, temporary separation of the teeth) and classify individual patients by caries risk category (see Appendix 2.)
- Reassess caries risk status regularly (not only in children but also elderly and medicated patients; see Appendix 2.)

WHEN TAKING A FILM-BASED RADIOGRAPH

- Use the appropriate radiograph for treatment planning.
- Use F-speed film for intraoral examinations and rare earth screens with spectrally matched film with an effective speed of 400 for extraoral examinations.
- If using wet film, consider using double-pack radiographs if referral is likely.
- Report radiographic findings in patient's notes.

WHEN TAKING A DIGITAL RADIOGRAPH

- Use the appropriate radiograph for treatment planning.
- Use rectangular collimation.
- Use suitable monitors for viewing digital radiographs, under optimum conditions and after adjustment of brightness and contrast settings.
- Ensure that phosphor plates or sensors are in good physical condition before use.

FOR ALL RADIOGRAPHS

- Ensure that processing conditions are satisfactory before processing a film.
- Ensure regular quality assurance in film processing or digital image production (eg. condition of plates and sensors, performance of sensors and plate readers).
- Use receptor-positioning and beam-aiming devices for intraoral films.
- Use an appropriate light box and magnifier for viewing, masking out any extraneous light.
- Mount, label and store radiographs appropriately.
- Follow national recommendations.¹
- Use exposure settings (kV, mA, time) chosen according to the imaging system used which will deliver acceptable diagnostic quality images with minimum patient dose.
- Send relevant existing radiographs when referring patients to colleagues.

9.1.2 *Don't*

- Carry out 'screening' radiographs or take radiographs as 'routine'.
- Take a new radiograph without examining existing radiographs.
- Take panoramic radiographs for all patients.
- Use a single protocol for all patients.
- Use an inappropriate light source for viewing.

9.2 IDEAS FOR AUDIT – DEVELOPING LOCAL GUIDELINES

Clinical audit is a statutory requirement¹ as well as a useful tool to help you improve your practice or simply check whether or not all members of the dental team meet the expected standards. It can be used for almost any procedure and is required as part of clinical governance for radiographs.

9.2.1 An audit to measure the quality of radiographs compared with NRPB guidelines (outcome audit)

The NRPB guidance describes three grades of radiograph quality based on the clinical value of the image. In essence, can one diagnose disease effectively from the radiograph? They assign the grades as excellent, diagnostically acceptable and unacceptable (Table 9.1).

Table 9.1: Quality assessment of radiographs

Ratings	Quality criteria	Targets: percentage of radiographs taken
1	Excellent – no errors of exposure, positioning or processing	Not less than 70%
2	Diagnostically acceptable – some errors of exposure, positioning or processing, but which do not detract from the diagnostic utility of the radiograph	Not greater than 20%
3	Unacceptable – errors of exposure, positioning or processing which render the radiograph diagnostically unacceptable	Not greater than 10%

The focus of the audit is simply whether or not the patient is gaining maximum benefit from the radiation exposure. It is still necessary to record why the radiograph does not meet the required standard, as before. A sufficient number of radiographs to provide a representative sample are also required. Again, it is a good idea to record

who was involved in making the exposure as well as the processing, so that good and poor performance can be identified.

9.2.2 Setting a standard

Firstly, you need to decide what standard you would like to achieve, along with a target and exceptions. The standard may be described in terms of an outcome, process or structure. Outcome means the end result you are looking for (such as: “over 70% of our radiographs will be grade 1, except in patients with a strong gag reflex”). Process relates to how you expect the patient to be cared for (such as: “95% of our patients will have justification, grade and reporting recorded on the computer or handwritten notes during the visit, except when the server has crashed”). Structure means the equipment or physical facilities (such as: “all of our x-ray machines should be less than ten years old, with the exception of the CT scanner at our City premises, which will be replaced after refurbishment”) (see Table 9.2).

Table 9.2: Summary of outcome, process and structure standards, targets and exceptions

	Outcome	Process	Structure
Standard	Grade 1 – No errors of patient preparation, exposure, positioning, processing or receptor handling	Justification, grading and reporting should be noted in the computerised records on the day of the patient’s visit	X-ray machines <10yrs old
Target	>70%	>95% of records have all three aspects noted	
Exception	Patients with a strong gag reflex	Days when the practice server is down	CT scanner at City premises

9.2.3 Involving all team members

Ideally, setting standards is a team effort. This helps to ensure that the whole team “buy in” to the changes that may be necessary. A preliminary discussion between team members responsible for these activities also makes everyone aware of the standards that the practice owners wish to achieve. This is often the most important aspect of any audit and can spontaneously lead to improvements in practice.

Some aspects of radiography best practice have already been established and can be found in resources such as the *Guidance Notes for Dental Practitioners on the Safe Use of X-Ray Equipment*,² the Health Protection Agency’s *Guidance on the Safe Use of Dental Cone Beam CT Equipment*³ and advice published by the British Dental Association (BDA). Manufacturers’ instructions can also be useful. Guidelines for good practice can then be drawn up and displayed in clinical areas as a reminder.

Setting the target for reaching the standard is the next aspect to consider. A 100% success rate in all aspects of dental radiography is ideal but highly unlikely. A lower target that will still provide a high standard of image whilst minimising radiation exposure is more realistic. Public Health England (PHE) has already recommended target for radiographs of >70% grade 1 and <10% grade 3. This allows for those difficult patients who gag, have missing teeth, etc. However, when it comes to stock control, you may feel it reasonable to expect that 100% of your radiographs are in date and stored correctly. When setting a standard, it is important to make a reasonable judgement, otherwise the team will not respect the audit process and are less likely to make the improvements you are looking for.

9.2.4 Gathering data

Most audits in dentistry are of outcome or process. Information needed to compare performance with standards can either be drawn from clinical records of patients seen in the past (an audit of retrospective data), or collected from patients from a given date onward (an audit of prospective data). Using retrospective data relies on good record-keeping during the period you are auditing. You should also ensure that the records relate to a time when you were practising in a similar way to your current practice. Otherwise you will only know how good you were with your old

technique, and will not learn much about your present technique. An audit of your x-ray grades of, say, six months ago would be useless if you had changed from film-based to digital x-rays in the last month.

All types of radiograph taken in a practice, which may include panoramic, cephalometric and CBCT images, as well as small intraorals, should be audited, even if the numbers taken are low. Using prospective data allows you to make observations that may not normally be recorded in the notes. You also need to be aware that you or your team may have an improved performance because you know you are being audited (known as the Hawthorne Effect). As audit is used to improve performance, then it can be argued that the desired effect has been achieved. It is also likely that team members will want to stick to the standard when they know what it is. The good thing about prospective audits is that everyone in the team has a good idea of what standard you want to meet and you know that your data is up to date.

Retrospective data can usually be gathered more quickly than prospective data, where you have to wait for enough of the right sort of cases to come into the practice.

COLLECTING DATA

Data is collected on a data capture form. It is worth taking a little time to think about this aspect of the process. A well-designed form will enable you to gather the right sort of data to compare how you are doing against your standard. It also needs to collect data to tell you why you are not meeting your standard. If you do not know why you are failing then you will not be able to improve. So, if you are getting a high number of grade 2 radiographs, is it because the positioning is wrong, or is it the processing or storage that is at fault? Having this level of data will allow you to identify where you need to make your changes and which team members need to be involved.

A data capture form needs a list of the criteria for the radiograph you are looking at, along with a comments box to record why it failed to meet your standard. It is also important to include details such as the names of the operator, processor or filing assistant, if you want to target your action plan to the individuals who are failing to meet the standard.

The next stage is to decide how to sample the radiography service in your practice. If you are performing a prospective audit, then it could be the next 50 bitewings or periapicals taken by the practice. However, it may be better to look at a sample of 20 for each operator. It is important to have a sampling protocol that provides a reasonable amount of data to provide a realistic impression of the practitioner's performance. However, it is not a good idea to choose such a large number that the data will take many months to collect.

In a retrospective audit, the data can be gathered much more quickly, but it has to be from a period when the procedures and techniques used are the same as those of the present day. It is also important to realise that audit is not research, and so will never provide statistically sound results. There is no need to create an audit to provide data that can stand up to statistical analysis. The purpose of audit is to encourage an improvement in standards. For this reason, it is better to have a short, sharp data gathering period where everyone remains engaged in the process, than a long drawn-out study.

9.2.5 Comparing standards

The next stage of the audit is to look at your current practice and record either what you are achieving (outcomes), doing (process) or have in place (structure). Then you can compare yourself against your standard and see if there are any ways you could improve. If the data capture form has been carefully designed, then a dental care professional (DCP) can often gather the data very easily. This involves them in the process and gives them a sense of ownership of any changes required.

Once the data has been collected, then it is compared with the standard set at the beginning. If you have designed your data capture form carefully, it should be obvious which aspects of the process and which team members are meeting the standard, and which are not. Ideally, the results and analysis are presented to the team. Care must be taken if there is underperformance to report. This is often better provided in private to the individual, with the results anonymised for the team meeting.

9.2.6 *Formulating an action plan*

The formulation of an action plan is the natural progression from the analysis. This may take the form of extra training (where an operator keeps missing the apex, for instance), producing a written set of instructions (when the team are not clear exactly how to label and file correctly), purchasing new equipment (if the developer keeps breaking down), or a host of other actions. If there are changes required, create an action plan with detailed steps, a finish date for each step and a named person responsible for overseeing it.

You will also need to evaluate if the plan has been successful, which is normally best done by a re-audit. The re-audit date should be set at a time that has allowed all of the changes to become embedded in the practice. The re-audit should occur very promptly for issues that carry a high health and safety risk, or could lead to a significant loss of service (a high business risk).

If you have achieved your goal, you may consider increasing the target or be content that you are practising to a very high level. In any event, you will need to set a re-audit date to ensure your practice is maintaining its high level of performance (a maintenance audit). This is a low-risk scenario, so a maintenance audit can be set several months or even years in the future.

Details are given here for two different approaches to a radiography audit. The first is about making good use of the resources in your practice, and ensuring that staff follow best practice when taking, developing, storing and labelling radiographs (a process audit). The second makes use of the former National Radiological Protection Board (NRPB, now part of PHE) guidelines for radiograph quality (an outcome audit).

9.2.7 *Audits involving teamwork in dental radiography (process audit)*

It is good clinical governance to aim for a consistently high standard of dental radiographs to ensure that maximum clinical value is obtained from the image, whilst radiation exposure is kept to a minimum for both patients and staff.

Much of the focus in dental radiography training is on the correct technique. However, it is no good taking a superb radiograph with perfect positioning and exposure if it is processed poorly, mis-labelled or mis-filed. This will mean that the radiograph will need to be repeated, unnecessarily raising the radiation exposure for the patient and using up time in the practice. Therefore, the whole team has a part to play in ensuring that there is a high standard of clinical governance in dental radiography.

Poor processing and storage could also have medico-legal consequences. Radiographs must be kept for 11 years or until the patient is 25 years of age, whichever is the longest (the counsel of perfection would be to retain records indefinitely).

Good radiograph record-keeping also includes appropriate justification, grading and reporting on the clinical notes.

Understanding the requirement for teamwork in the whole process of clinical governance for radiographs opens up many opportunities for auditing the quality of your practice's radiographs.

Here are some suggestions for some simple audits to help improve the quality of your radiographs:

- Stock control of unused radiographs: Is stock out of date? Is it stored correctly?
- Processing: Were they developed, washed and dried correctly? Is there a programme for changing the developer fluids before they lose their potency? Is equipment maintained?
- Mounting, labelling, and filing: Was it done correctly and in time for the patient's next appointment?
- Record-keeping: Is there a record of the justification for the radiograph? Has the grade been recorded? Is there a report of the clinical findings?
- Checking equipment: Visually inspect and record the condition of phosphor plates or digital sensors and all other parts of the equipment.

The above four bullet points apply to wet radiographs. The bullet points about labelling (clear identification) and record-keeping also apply to digital radiographs.

Some practices grade their radiographs as soon as they are processed (usually by a DCP), providing an ongoing series of data. This can be very useful if the person grading the radiographs has been trained adequately. However, anecdotal evidence suggests that the DCP will often give every radiograph a grade of 1, even when they are of very poor quality. The practice will then appear to have a spectacular level of performance. Any regulator that discovers an inadequate grading process could become rightly suspicious that the practice owner is not taking their responsibilities of clinical governance seriously. This may lead them to delve a little deeper into other aspects of the practice's health and safety procedures.

It should also be noted that merely collecting grades without stopping to collate and analyse the data is not really audit, either. Any good clinical governance system will do this at regular intervals and have a record of the team meeting and any necessary action plan.

Quality assessment of cone beam computed tomography (CBCT) examinations has been addressed by the Health Protection Agency Working Party.³ In view of the potential radiation dose implications of this technique and the more reliable image capture, a more stringent performance target has been set. It recommended that no more than 5% of examinations should be graded as diagnostically unacceptable. No "excellent" grading was included because the presence of metallic restorations inevitably leads to artefacts in CBCT. This resulted in a target of not less than 95% of examinations being rated as diagnostically acceptable. Users of CBCT are strongly advised to refer to this document for further details.³

9.3 MORE AUDIT IDEAS

An initial audit may highlight areas worth investigating in more detail, or may show up other problems not considered first time around. The focus of each re-audit can easily be tailored to meet the needs of the practice at the time. Some areas to consider are:

- Darkroom facilities.
- Radiographic image quality.
- Routine surveillance of equipment.
- Record-keeping of routine events and accidents.
- Daily evaluation of processing equipment using a test object.
- Weekly checks on the number of radiographs taken.
- Protection for staff, and monitoring.
- Weekly checks on radiographic workload.
- Factors not listed above specific to digital radiographs.

Recommendations have been published² for assessing quality of radiographs using a three-point scale (Table 9.1). These lend themselves to audit, and data analysis is kept simple. A more detailed look at reasons for poor quality could then be reviewed with re-audit.

Recommended Further Reading

British Dental Association (BDA). *BDA Advice – Radiation Protection*. October 2017. Available at www.bda.org (Members Area).

9.4 REFERENCES

1. Department of Health. The Ionising Radiation (Medical Exposure) Regulations 2017. London: Department of Health; 2017.
2. National Radiological Protection Board (NRPB). Guidance notes for dental practitioners on the safe use of x-ray equipment. NRPB: Chilton; 2001.
3. Health Protection Agency. Guidance on the safe use of dental cone beam CT. London: HPA; 2010.

Appendix 1

Overview of
recommendations

Overview of recommendations

(No radiographs should be taken until a history and clinical examination have been performed)

Patient category		Dentate			Edentulous	
NEW PATIENT	SELECTION CRITERIA	CHILD-PRIMARY DENTITION	CHILD-MIXED DENTITION	ADOLESCENT	ADULT	
	All new patients, to assess dental diseases, growth and development	Posterior bitewing examination as indicated after clinical examination	Patient-specific radiographic examination as indicated after clinical examination	Patient-specific radiographic examination consisting of posterior bitewings and selected periapicals. An extensive intraoral radiographic examination may be appropriate when the patient presents with clinical evidence of generalised dental disease or a history of extensive dental treatment. Alternatively, a panoramic radiograph may be appropriate in some instances (see Section 2.2)		
RECALL PATIENT	Growth and development	Not normally indicated	Patient-specific radiograph indicated after clinical examination	Not normally indicated. One-off periapical or panoramic examination to assess development of third molars if symptomatic		
	See Appendix 2. Reassess caries risk at each visit	High caries risk	Posterior bitewing examination at six-month intervals* or until no new or progressing carious lesions are evident. Bitewings should not be taken more frequently and it is imperative to reassess caries risk in order to justify using this interval again.			Not applicable
		Moderate caries risk	Posterior bitewing examination at one-year intervals*			Not applicable
		Low caries risk	Posterior bitewing examination at 12-18-month intervals*	Posterior bitewing examination at two-year intervals*. More extended radiographic recall intervals may be employed if there is explicit evidence of continuing low caries risk		Not applicable
	Periodontal disease or history of periodontal disease	Patient-specific radiographic examination consisting of selected periapical and/or bitewings for areas where periodontal disease (other than non-specific gingivitis) can be demonstrated clinically			Not applicable	

*For children and young people, consider also the alternative frequency of bitewing examinations recommended by the EAPD (see Section 4A).

Appendix 2

Selection criteria for radiographs according to caries risk status

REFERENCES

1. [R] Beal JF. Social factors and preventive dentistry. In: Murray JJ, editor. The prevention of oral disease. Oxford: Oxford University Press; 1996. p.216-233.
2. Smith P, Nugent Z, Pitts NB. The burden of delay in seeking dental treatment in the Scottish GDS [abstract 395]. J Dent Res 1996;75:1179.
3. Gustaffson BE, Quensel CE, Lanke LS, Lundqvist C, Grahnen H, Bonow BE, et al. The Vipeholm dental caries study; the effect of different levels of carbohydrate intake on caries activity in 436 individuals observed for five years. Acta Odontol Scand 1954;11:232-364.
4. [R] Shou L. Social and behavioural aspects of caries prediction. In: Johnson NW, editor. Dental Caries: Markers of High and Low Risk Groups and Individuals. Cambridge: Cambridge University Press; 1991. p.172-97.
5. [R] Tenovuo J. Salivary parameters of relevance for assessing caries activity in individuals and populations. Community Dent Oral Epidemiol 1997;25:82-6.
6. [R] Hobson P. Sugar-based medicines and dental disease. Community Dent Health 1985;2:57-62.
7. [R] Rugg-Gunn AJ. Diet and dental caries. In: Murray JJ, editor. The prevention of oral disease. Oxford: Oxford University Press; 1996. p.3-31.
8. [R] Murray JJ, Naylor MN. Fluorides and dental caries. In: Murray JJ, editor. The Prevention of Oral Disease. Oxford: Oxford University Press; 1996. p.32-77.
9. [R] Koch G, Arneberg P, Thylstrup A. Oral hygiene and dental caries. In: Thylstrup A, Fejerskov O, editors. Textbook of clinical cariology, 2nd ed. Copenhagen: Munksgaard. 1994: p.219-30.
10. [R] Sutcliffe P. Oral cleanliness and dental caries. In: Murray JJ, editor. The Prevention of Oral Disease. Oxford: Oxford University Press; 1996. p.68-77.
11. [R] Hausen H. Caries prediction – state of the art. Community Dent Oral Epidemiol 1997;25:87-96.
12. [R] Johnson NW, editor. Dental caries: markers of high and low risk groups and individuals. Cambridge: Cambridge University Press, 1991.
13. [R] Gordon PH, Nunn JH. Fissure sealants. In: Murray JJ, editor. The prevention of oral disease. Oxford: Oxford University Press; 1996. p.78-94.
14. Zachrisson BU, Zachrisson S. Caries incidence and orthodontic treatment with fixed appliances. Scand J Dent Res 1971;79:183-92.
15. Zachrisson BU, Zachrisson S. Caries incidence and oral hygiene during orthodontic treatment. Scand J Dent Res 1971;79:394-401.
16. Yamaga T, Komoda Y, Soga K, Ono M, Asada T, Itosaka N, et al. Root surface caries of denture wearers in middle aged and elderly people. J Osaka Univ Sch Dent 1994;34:65-71.
17. Drake CW, Beck JD. The oral status of elderly removable partial denture wearers. J Oral Rehabil 1993;20:53-60.

Selection criteria for radiographs according to caries risk status for children and adults

Risk category	Radiographic guidelines	CARIES RISK ASSESSMENT						
		Social history	Medical history	Dietary habits	Use of fluoride	Plaque control	Saliva	Clinical evidence
High caries risk	Posterior bitewing radiographs at six-month intervals until no new or active lesions are apparent and patient's risk category changes. Bitewings should not be taken more frequently. It is imperative to reassess caries risk to justify using this interval again. Remember that the rate of caries progression in enamel and dentine will differ, and may be slower in adults than in children.	<ul style="list-style-type: none"> • Socially deprived^{1R} • High caries in siblings^{1R} • Low knowledge of dental disease^{1R} • Irregular attender² • Ready availability of snacks³ • Low dental aspirations^{1R} 	<ul style="list-style-type: none"> • Medically compromised^{4R} • Disabled^{4R} • Xerostomia^{5R} • Long-term cariogenic medicine^{6R} 	<ul style="list-style-type: none"> • Frequent sugar intake^{6R,7R} 	<ul style="list-style-type: none"> • Drinking-water not fluoridated^{8R} • No fluoride supplements^{8R} • No fluoride toothpaste^{8R} 	<ul style="list-style-type: none"> • Infrequent ineffective cleaning^{9R,10R} • Poor manual control^{9R,10R} 	<ul style="list-style-type: none"> • Low flow rate^{5R} • Low buffering capacity^{5R} • High S Mutans and Lactobacillus counts^{11R,12R} 	<ul style="list-style-type: none"> • New lesions, premature extractions, anterior, caries or restorations, multiple restorations^{11R} • No fissure sealants^{13R} • Fixed appliance orthodontics^{14,15} • Partial dentures^{16,17}
Moderate caries risk	Annual posterior bitewings unless risk status alters	INDIVIDUALS WHO DO NOT CLEARLY FIT INTO HIGH OR LOW CARIES RISK CATEGORIES ARE CONSIDERED TO BE AT MODERATE CARIES RISK Note that the patient's risk status should be reassessed at subsequent visits, and appropriate action should be taken if their risk status changes						
Low caries risk	Posterior bitewing radiographs at approximately: 12-18-month intervals in primary dentition Two-year intervals in permanent dentition More extended radiographic recall intervals may be employed if there is explicit evidence of continuing low caries risk	<ul style="list-style-type: none"> • Socially advantaged • Low caries in siblings • Dentally aware • Work does not allow regular snacks • High dental aspirations 	<ul style="list-style-type: none"> • No medical problem • No physical problem • Normal salivary flow • No long-term medication 	<ul style="list-style-type: none"> • Infrequent sugar intake 	<ul style="list-style-type: none"> • Drinking-water fluoridated^{8R} • Fluoride supplements used • Fluoride toothpaste used 	<ul style="list-style-type: none"> • Frequent effective cleaning • Good manual control 	<ul style="list-style-type: none"> • Normal flow rate • High buffering capacity • Low S. mutans and Lactobacillus counts 	<ul style="list-style-type: none"> • No new lesions • No extractions for caries • Sound anterior teeth • No or few restorations • Restorations inserted years ago • Fissure-sealed • No appliance

Appendix 3

Care pathways -
a framework for
decision support
and audit

OTHER STANDARDS AND GUIDANCE PUBLICATIONS FROM THE FGDP(UK)



Antimicrobial Prescribing for General Dental Practitioners

Antimicrobial Prescribing for General Dental Practitioners provides guidance on the prescribing of antimicrobials to adults and children in primary dental care. It gives clear, simple and practical advice on when to prescribe, what to prescribe, for how long and at what dosage. An invaluable asset in any dentist's library, the current edition reflects changes to recommendations since the previous (2006) update, and includes dosage recommendations for children for the first time.


- Available in hard copy format, e-book format, and free-of-charge online.



Clinical Examination and Record-Keeping: Good Practice Guidelines

Covering dental records, history-taking, full examination, recall visits, consent, confidentiality, data protection, referrals, electronic records, special situations and more, this third edition of *Clinical Examination and Record-Keeping* has been fully updated and expanded to reflect technological and regulatory developments, and introduces a simple 'ABC' system for grading its recommendations. The hard copy also includes scenarios to put the guidance into context, as well as a series of extensive appendices, diagrams, charting notes and template forms which dental professionals may adopt for use in their practice.

- Available in hard copy format and free-of-charge online.



Dementia-Friendly Dentistry: Good Practice Guidelines

With the number of people living with dementia rising primary care dental teams are encouraged to consider ways they can improve support and care for this patient group.

Dementia-Friendly Dentistry: Good Practice Guidelines offers clear, evidence-based and practical information and recommendations categorised using the Faculty's 'ABC' grading system.

- Available in hard copy format (and free-of-charge online from mid-2018).



Standards in Dentistry

Standards in Dentistry brings together all previous standards and guidelines in oral healthcare, including material published by the FGDP(UK), BDA, GDC, ISO, and the Department of Health, among others. The comprehensive manual includes tables of clinical outcomes, based on the FGDP(UK)'s previous publication Self-Assessment Manual and Standards (SAMS), covering 17 treatment areas in both primary and secondary care dentistry. This ambitious package is an indispensable compendium for the conscientious oral healthcare professional in helping to guide personal or practice-based quality assessment.

- Available in hard copy format with accompanying online access for purchasers.

Selection Criteria for Dental Radiography



Faculty of General Dental Practice (UK)
35-43 Lincoln's Inn Fields
London WC2A 3PE
Tel: 020 7869 6754 Fax: 020 7869 6765
Email: fgdp@fgdp.org.uk Website: www.fgdp.org.uk

Registered Charity No. 212808
